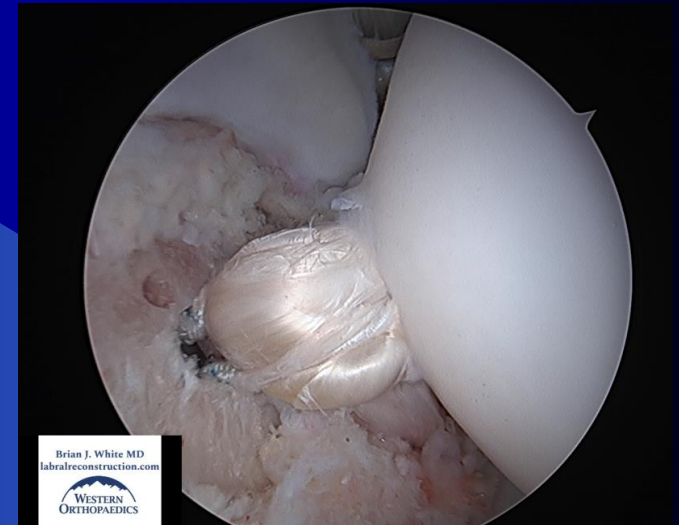

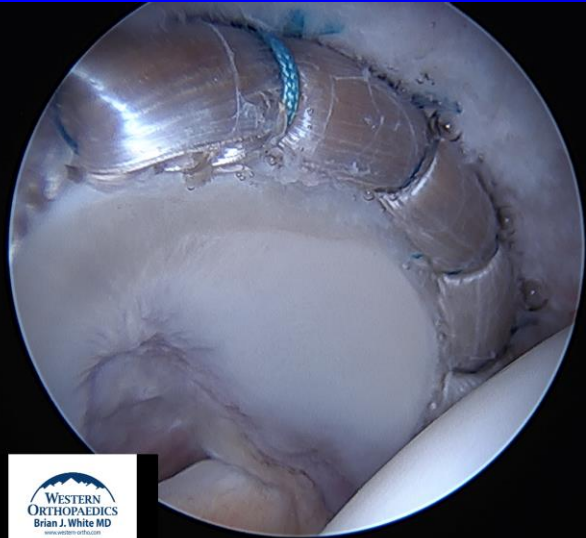


A Patient's Guide to: Arthroscopy of the Hip

Brian J. White MD

Western Orthopaedics - Denver, Colorado

www.labralreconstruction.com



Swedish
Medical Center
Hip Restoration Institute

Introduction

- This is designed to provide you with a better understanding of:
 - Anatomy of the Hip
 - Biomechanics of the Hip joint
 - The rationale behind Hip Arthroscopy
 - Expectations of the procedure



Excellence in Motion

Disclosures

- I am a Consultant for Hip Arthroscopy in two ways:
 - Education
 - I teach Orthopaedic Surgeons around the world how to safely access the Hip arthroscopically and treat FAI and Reconstruct the Labrum
 - This is done with visits and labs in Denver and with Broadcast Surgeries from my OR to them
 - New Product development
 - I help design instrumentation to improve both the safety and technique of Hip arthroscopy

My Training

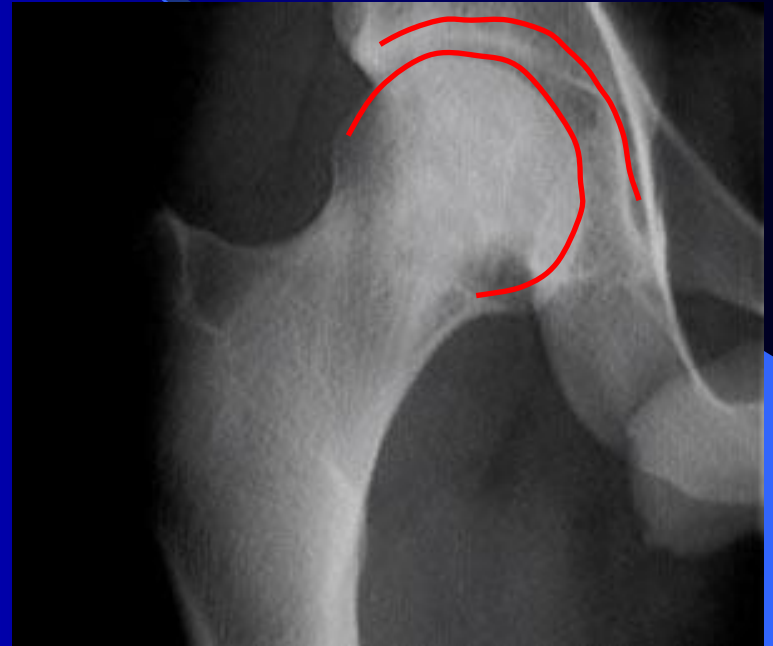
- Washington and Lee University
 - BA Chemistry
- Georgetown University School of Medicine
 - Medical Degree
- NYU/Hospital for Joint Diseases
 - Orthopaedic Surgical Residency
 - Shock Trauma-Baltimore, MD-advanced Fracture Care
- Steadman Philippon Research Institute: Vail, CO
 - Sports Medicine Fellowship in Knee, Shoulder and Hip
 - Mentors: Dr. Steadman and Dr. Philippon

Femoracetabular Impingement (FAI) and Labral Tears

- On average, Patients with this Problem see 4 physicians and wait 2 years before the appropriate diagnosis is made.
- Though this is an old study, I still experience this today...

Anatomy

- The hip is a ball and socket joint formed by two bony structures
 - The Femoral Head or Ball
 - The Acetabulum or Cup
 - They need to be perfectly fit for one another



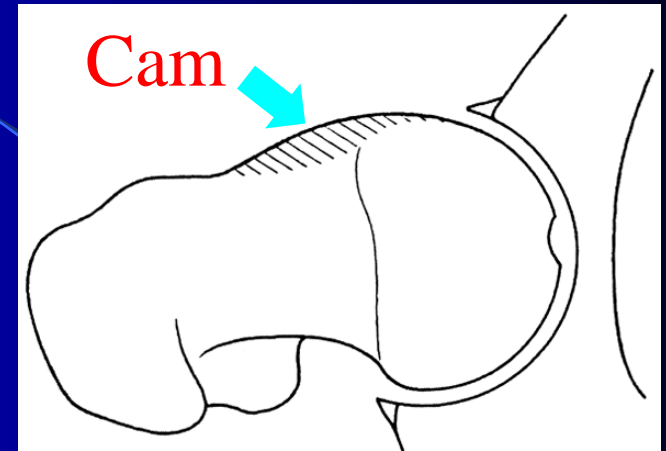
What is FemorAcetabular Impingement (FAI)?

- The Ball and Cup are not perfectly shaped for each other.
- With normal rotation of the imperfectly shaped hip joint, there is an abnormal contact between the two sides of the joint.
- This is the impingement which can lead to tearing of the labrum and/or cartilage.
- Impingement itself is not painful – the pain comes from the labral tear

There are Two types of FAI

● CAM type:

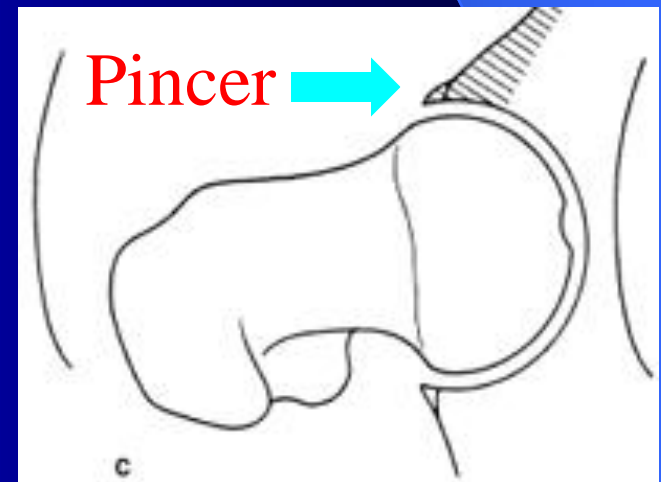
- Ball is oval shaped rather than round
- With Hip rotation it does not fit fully into the round Cup



Shaded areas represent the bone that shouldn't be there

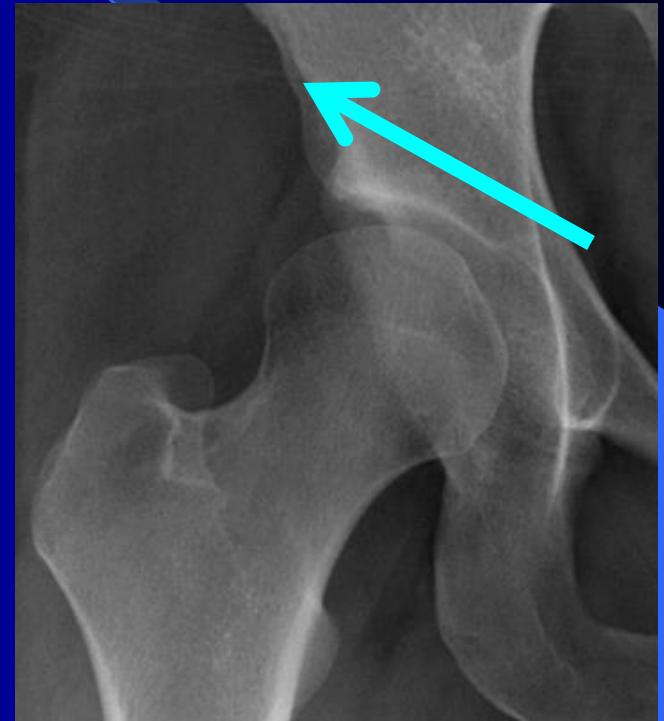
● PINCER type:

- The Cup over covers the Ball
- This prevents the Ball from fitting properly into the Cup



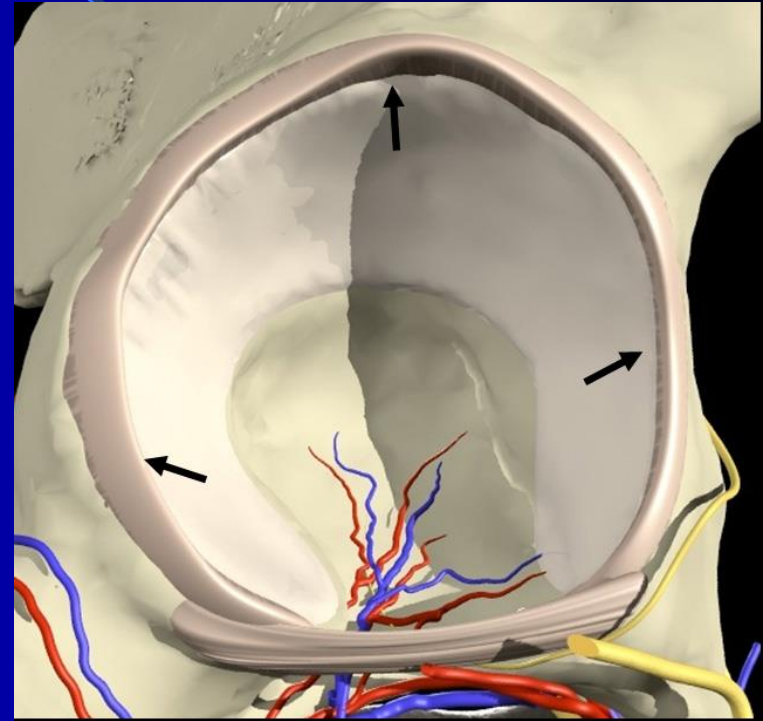
What is Hip Dysplasia?

- A shallow cup that does not fully contain the ball
- Results in overload to the edge of the joint
- It often leads to tearing of the labrum and premature degenerative arthritis of the hip joint
- This can be treated with a Ganz Osteotomy- I have a separate presentation on this.



Acetabular Labrum

- The Labrum is a soft tissue extension off of the Cup-kind of like cartilage
- It can tear because of underlying FAI
- When it is torn it can be quite painful
- Function of Labrum:
 - Forms a seal with the Ball to contain joint fluid
 - Similar to a washer on a facet
 - Contributes to stability of the Hip
 - Protects Cartilage of the Cup



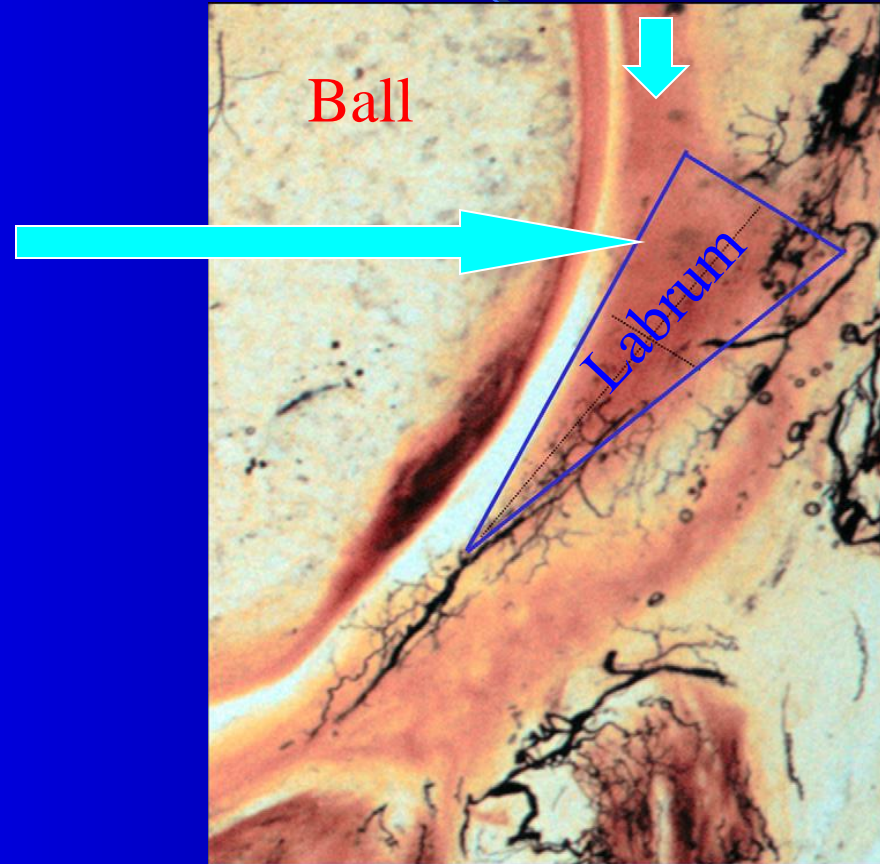
Why is the Labrum Important?

- Enhances Acetabular Volume by 20%
- Forms a Seal with the Femoral Head
- Provides Stability to the Hip
- Contains the Joint fluid for Cartilage Nutrition
- Protects cartilage on the cup from sheer force
- Fatal Flaw-it is highly innervated with pain fibers and is quite painful when torn

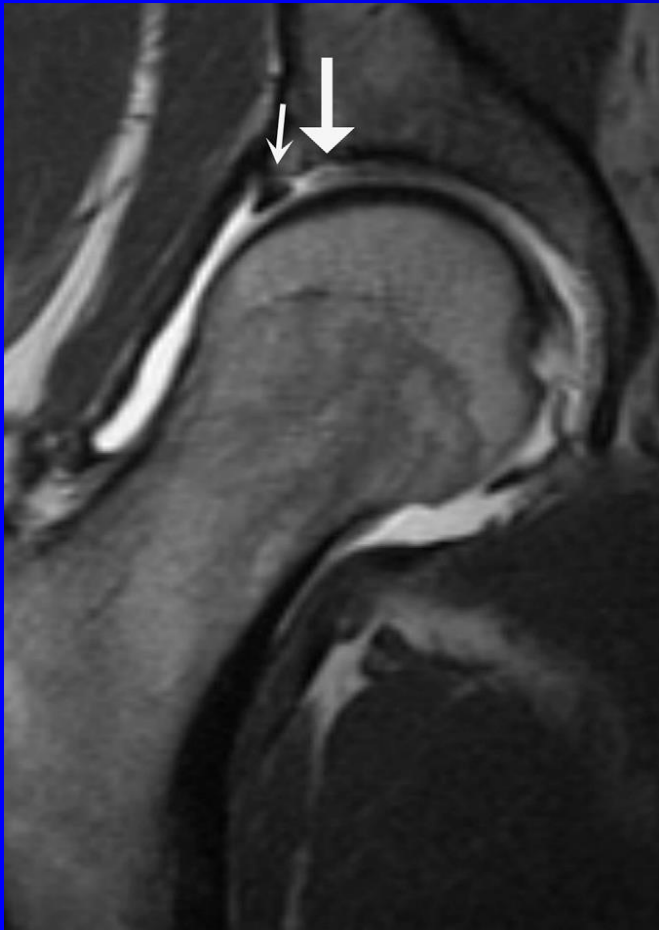
Labral Cross Section

Cartilage on Cup

The Cartilage and the labrum run together. This means that when the labrum is torn often the cartilage is damaged as well. This injury can be the beginning of Arthritis of the Hip.

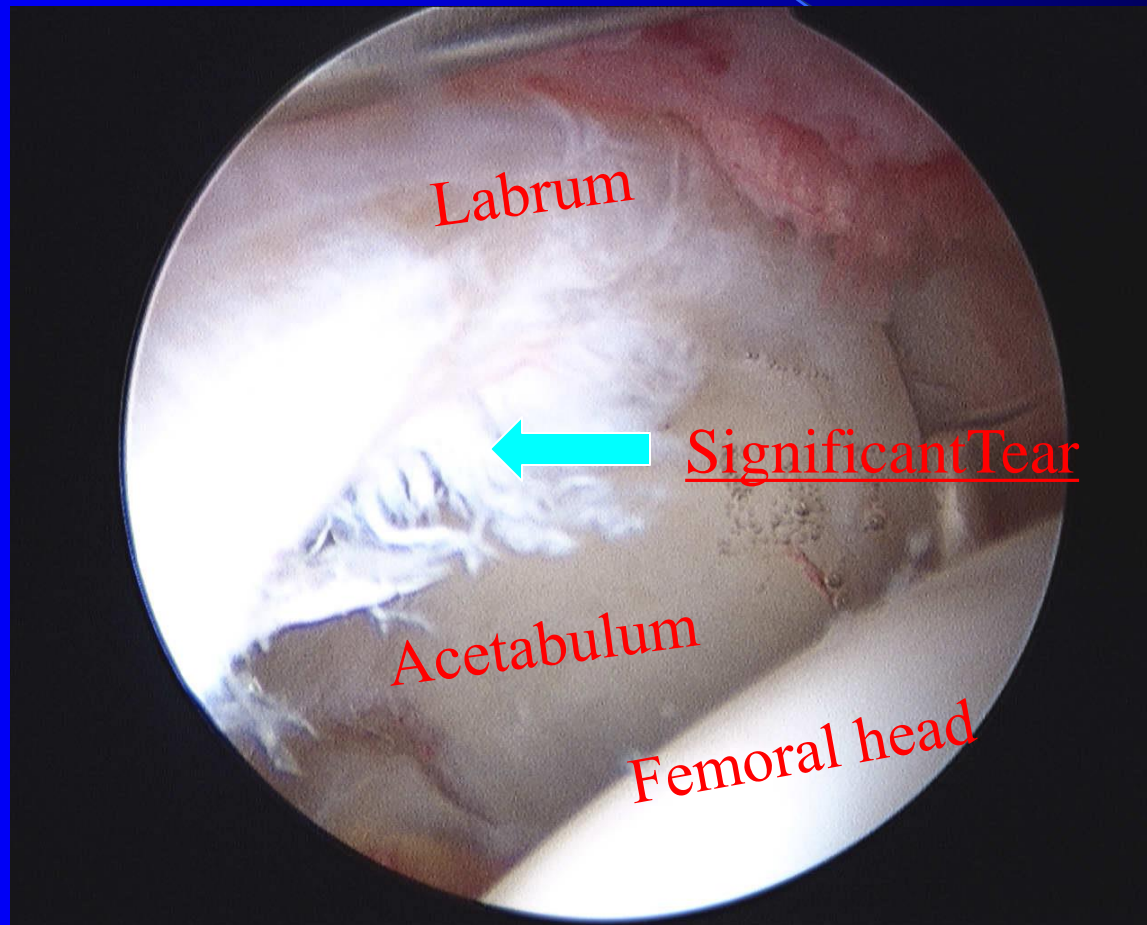


MRI with Arthrogram



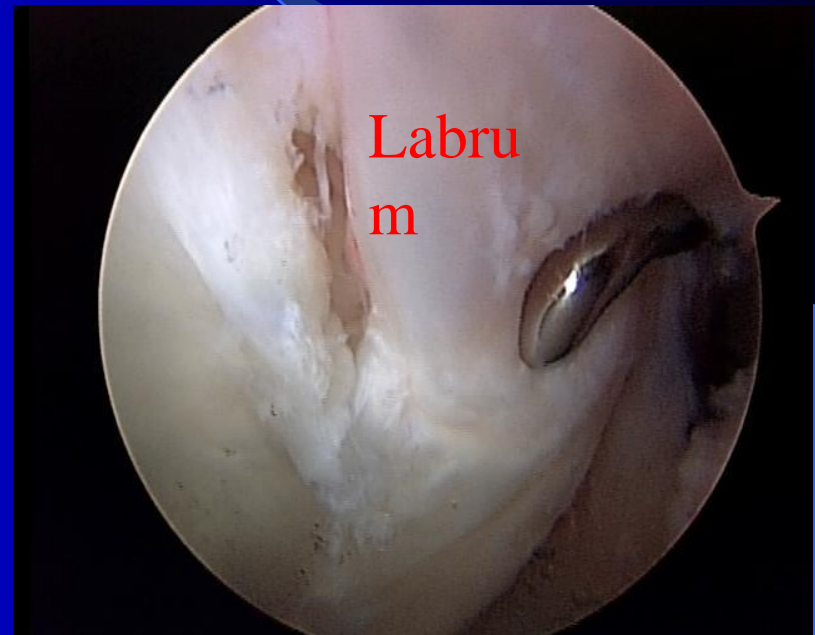
- An MRI done with an injection is the best type of imaging that we have now.
- A 3T MRI is the best quality
- However, it is NOT perfect and does miss some labral tears
 - Either it is misread by the Radiologist or the quality of the MRI makes it hard to see

Read as a “Normal” MRI



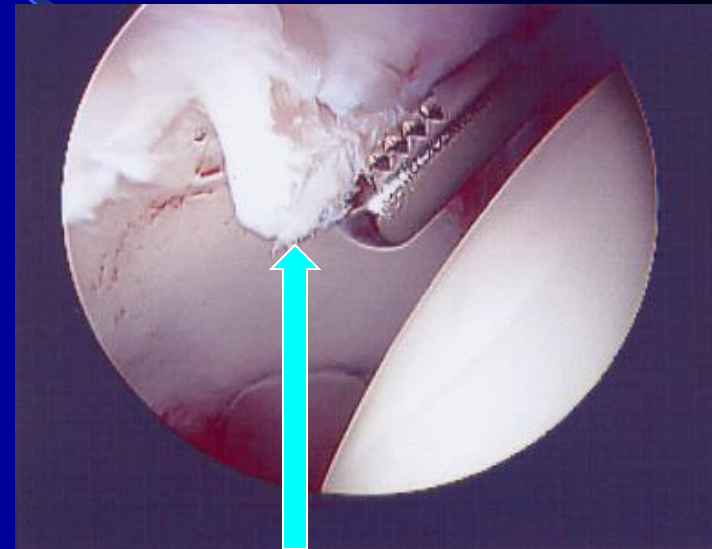
Acetabular Labral Tears

- Most tears are from minor, subtle injuries or none at all
- Almost all occur in conjunction with FAI
- Symptoms: groin pain worsened with use, pivoting or long sitting (can also be felt on the side, buttock or thigh)
- Occasionally there can be clicking or catching



The Problem with CAM FAI

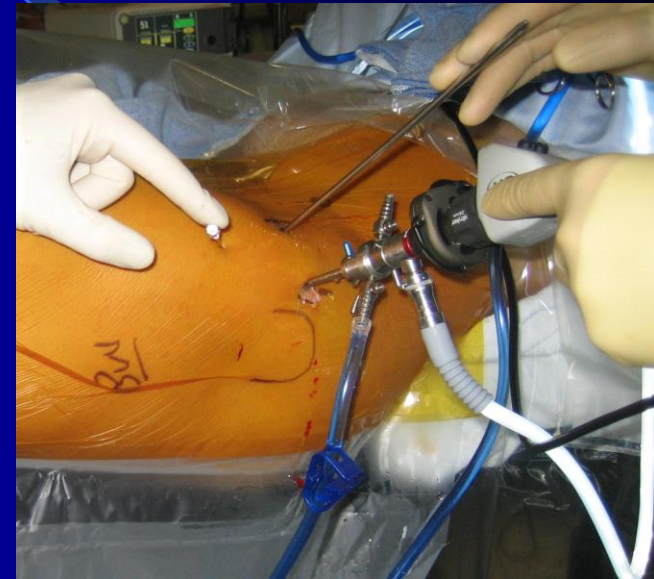
- Severe CAM type of FAI can injure the cartilage when it tears the labrum
- Sometimes, the cartilage of the Cup can peel off of the bone. If present:
 - The cartilage can not be re-attached
 - May require a Microfracture procedure to try and make a new cartilage patch



Cartilage peeling off of cup

Hip Arthroscopy

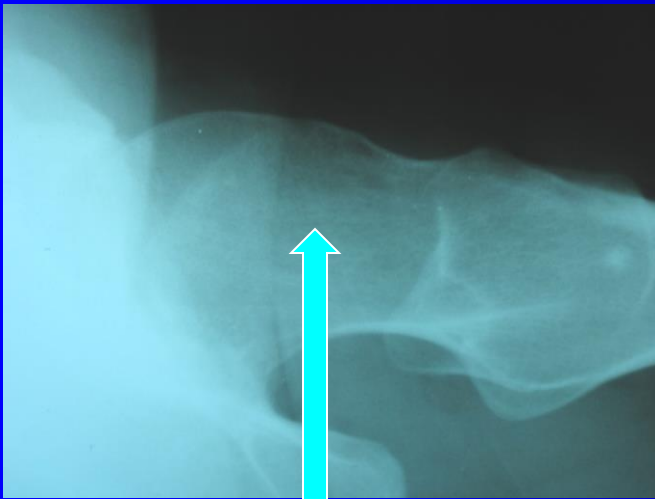
- Basic Arthroscopic procedures for the hip were first described for the hip in the 1970's
- But the evolution of this surgery has been slow because:
 - The Hip is deep within the body and is difficult to get to (unlike the shoulder and the knee)
 - Poor understanding of problems that can occur with the Hip joint
 - We lacked the appropriate instruments to safely operate on the Hip Arthroscopically



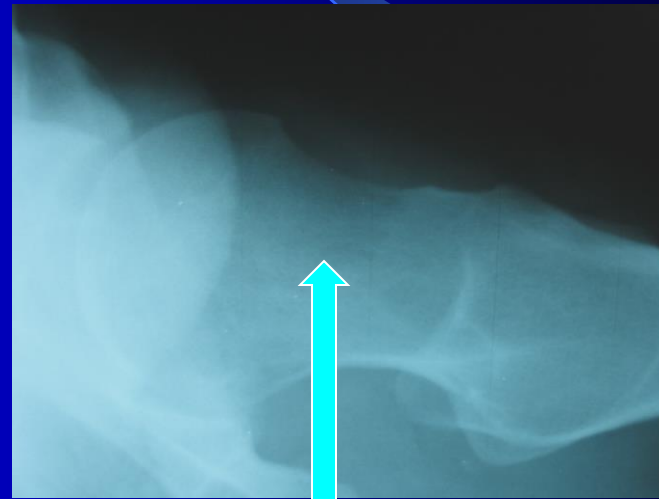
Hip Arthroscopy Now

- Hip Arthroscopy has evolved significantly in the last several years to treat Labral tears and FAI.
 - CAM- the Ball can be reshaped to make it round
 - Pincer- the Cup can be trimmed back to treat the overcoverage.
 - Labral Tear- Suture anchors can repair Labrum or a new one can be made (Reconstruction)
 - Cartilage Injury:
 - Can be shaved to stabilize the loose cartilage
 - Microfracture procedure can be done to regenerate cartilage
 - Ligamentum Teres Reconstruction
 - Ganz Osteotomy
 - Greater Trochanteric Bursectomy

Reshaping the ball to make it Round - Femoral Osteoplasty

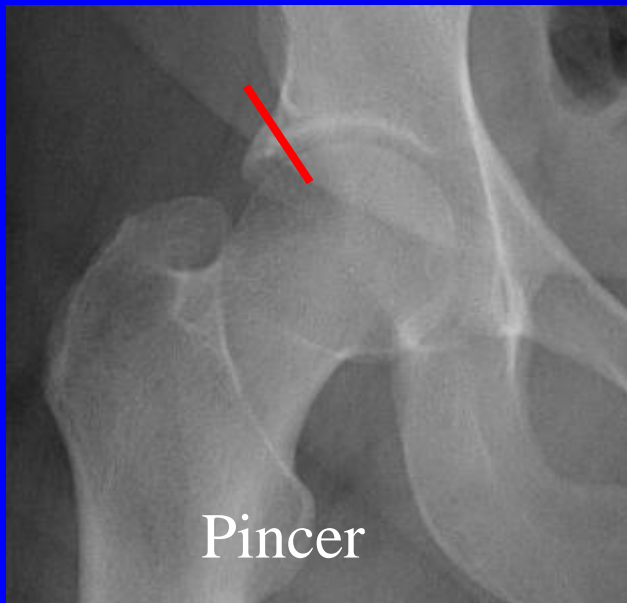


Before surgery-note
oval shape

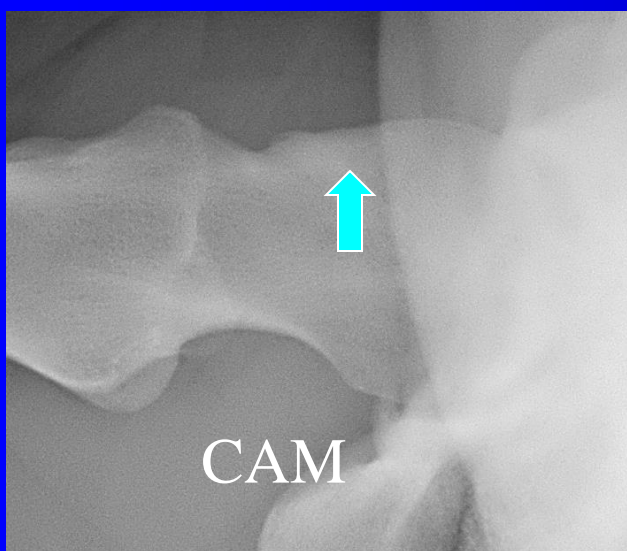
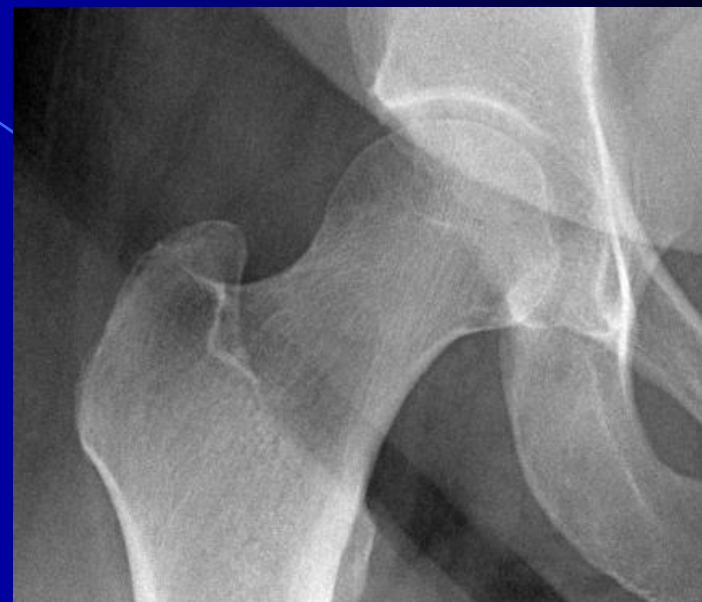


After surgery-bone
removed to make it round.
Now it will fit better into
the cup

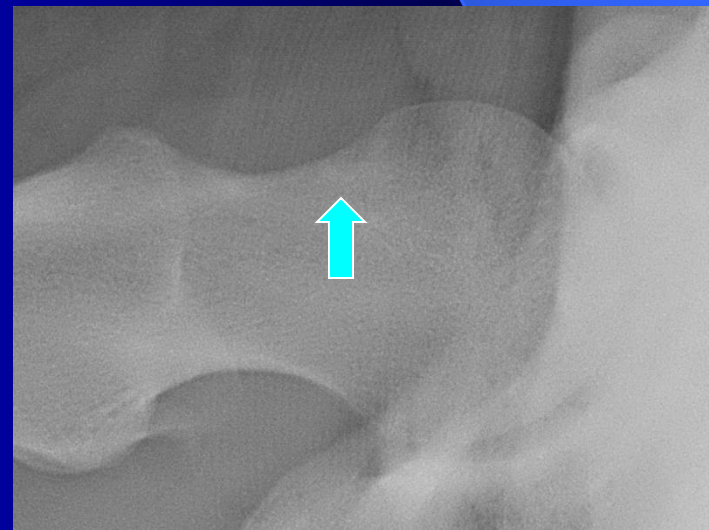
FAI Treatment



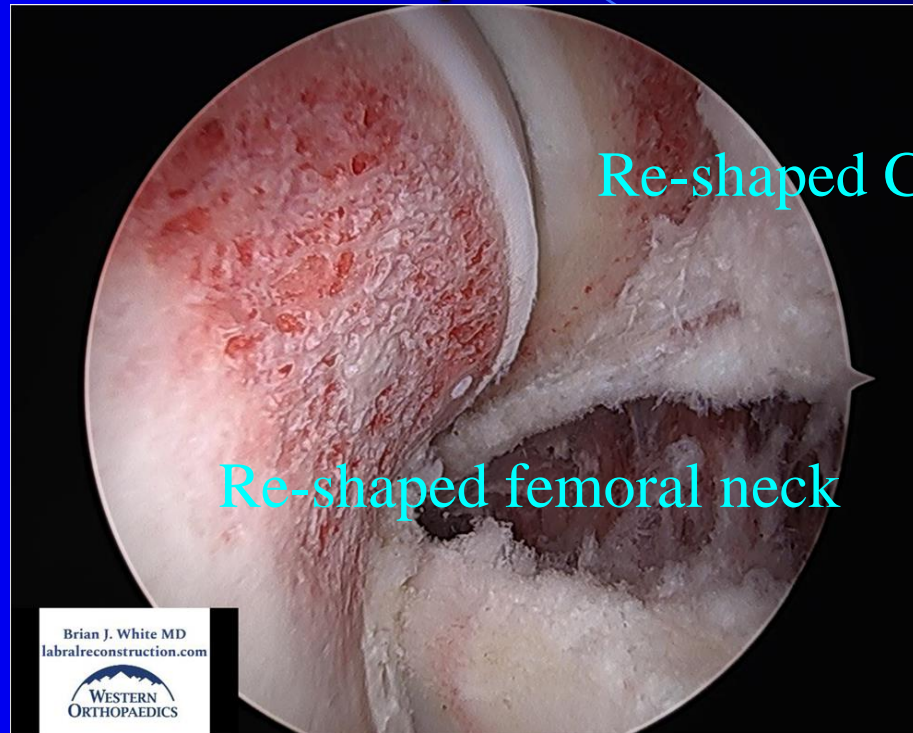Re shaping
the cup



Re-shaping
the ball

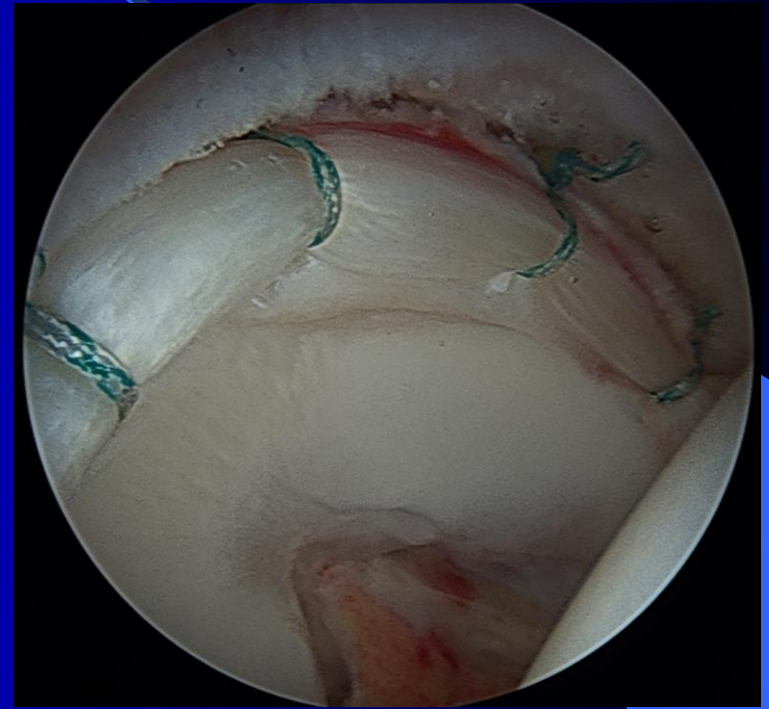

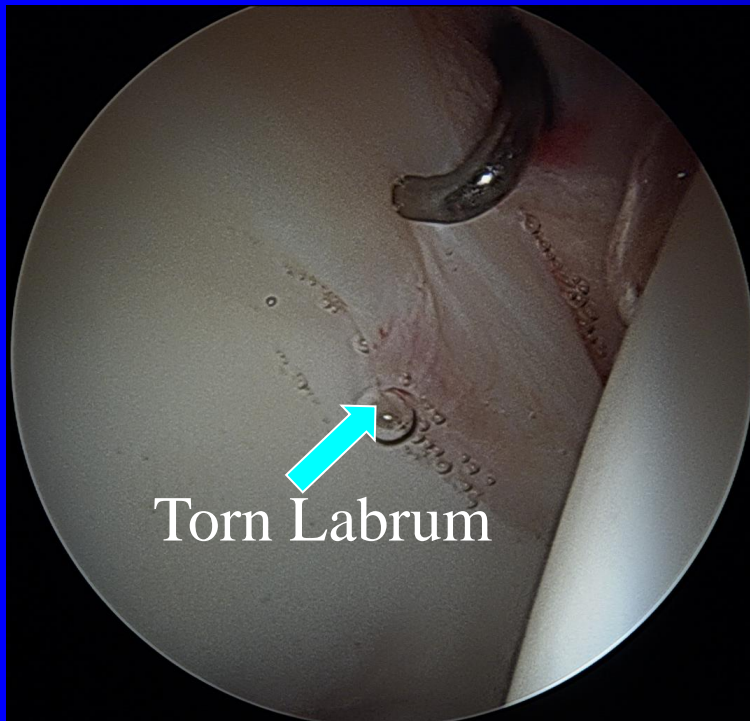


Proper Re-shaping of the Ball and the Cup is Essential



- This is my standard. Meticulous Reshaping is paramount to an excellent long term result.
- I spend 1 ½ to 3 hours re-shaping both the ball and the cup so that the fit is perfect and your labral graft is protected

Labral Repair

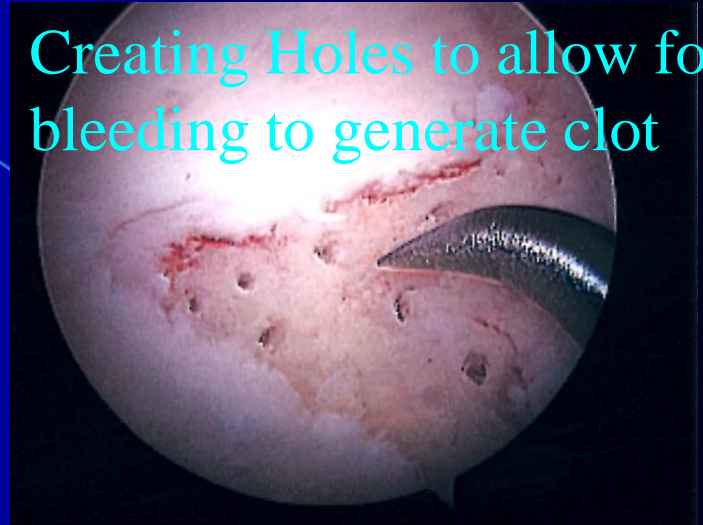

- This is an example of my labral repairs. I no longer repair the labrum as the results are not consistently good and my results have been much better and more consistent with Labral Reconstruction

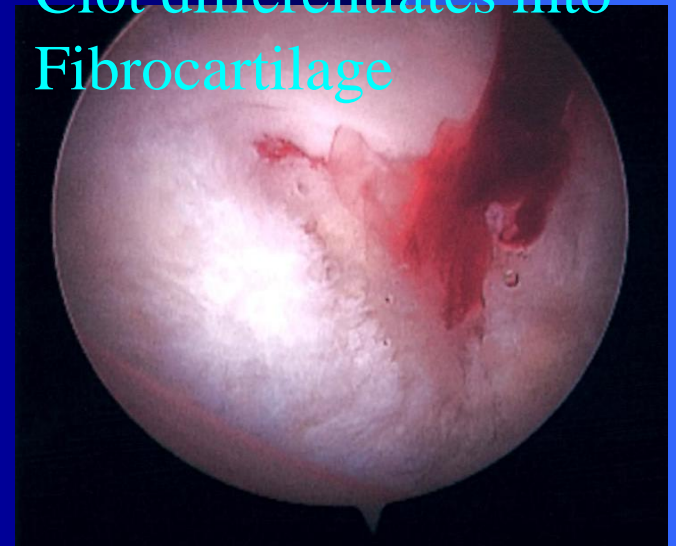
Microfracture Procedure

- Performed when cartilage has peeled off of the cup
- Generates a type of scar cartilage to fill the defect-not as durable as real cartilage
 - This is similar to repairing a pothole on a road-it is not the same.
- The Rehabilitation for this is different:
 - 6 wks of crutches (rather than 4)
 - 6 wks of using the CPM or bending machine for 6-8 hrs per day (rather than 2 wks)
 - This protects the clot and allows it to properly mature

Creating Holes to allow for bleeding to generate clot

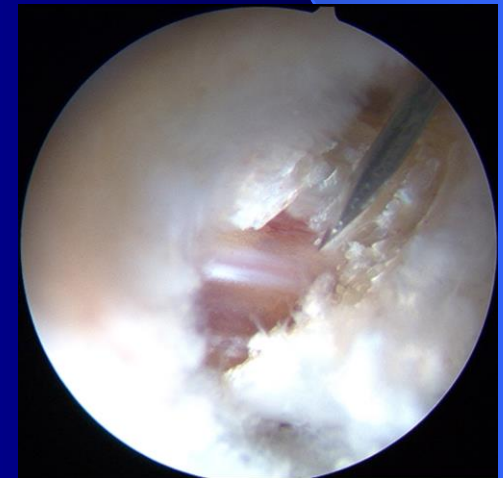
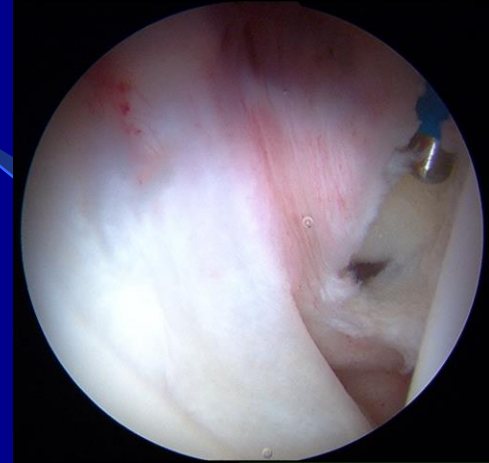


Clot differentiates into Fibrocartilage



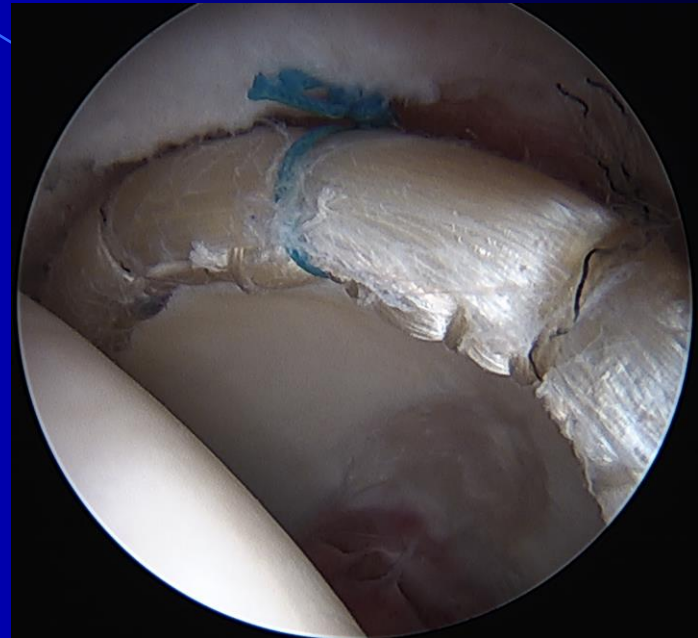
Iliopsoas Tendon Release?

- Sometimes the Iliopsoas tendon can pop over the hip joint and the torn labrum causing pain.
- In the past the tendon was lengthened.
- I do not perform this anymore as it can imbalance the hip muscles and cause weakness with hip flexion
- Typically, the popping improves once the hip joint is fixed and the muscles are balanced with Physical Therapy.



Labral Reconstruction

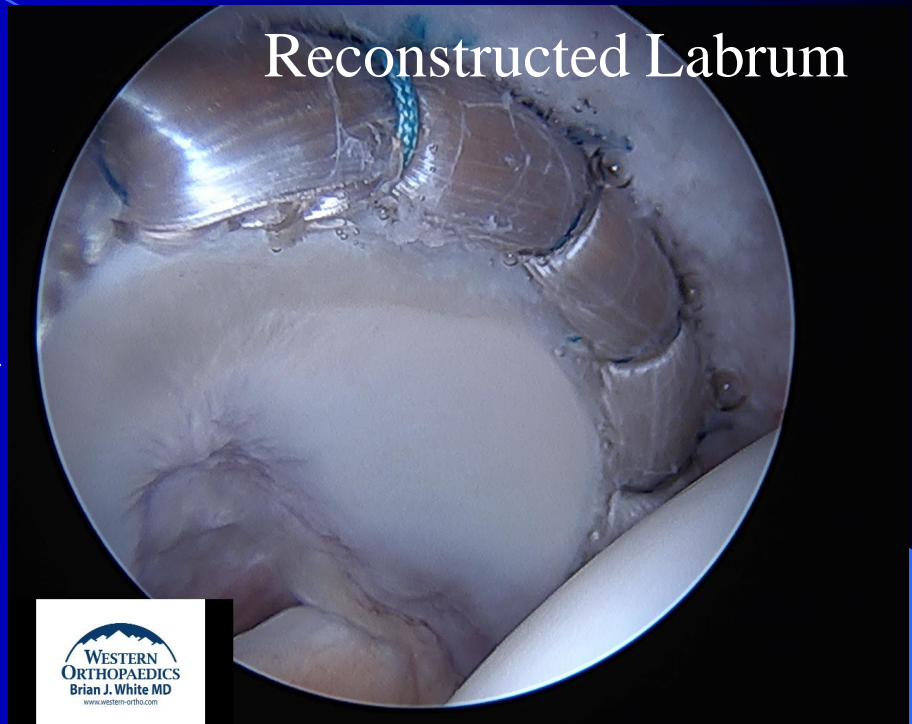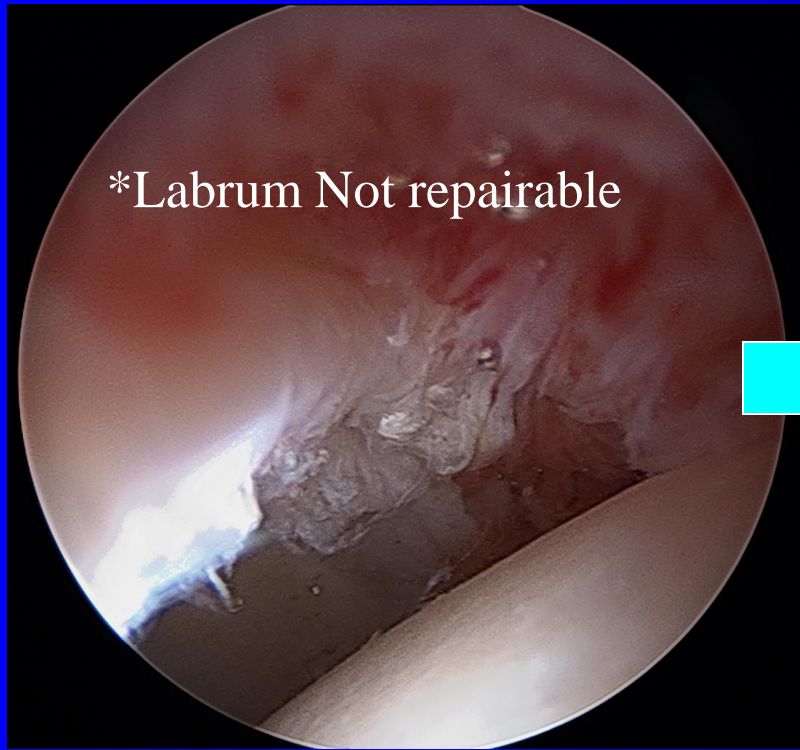
- I make a New labrum from a Cadaver Graft.
- Everything is performed arthroscopically.
- This is my treatment for labral tears.



NEW labrum made from IT band from a Cadaver Graft

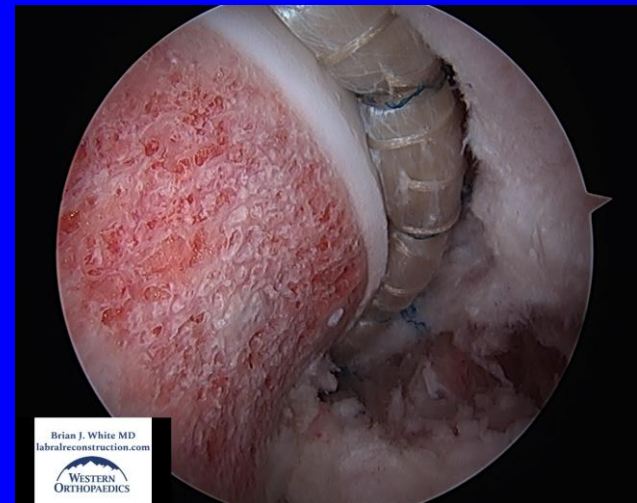
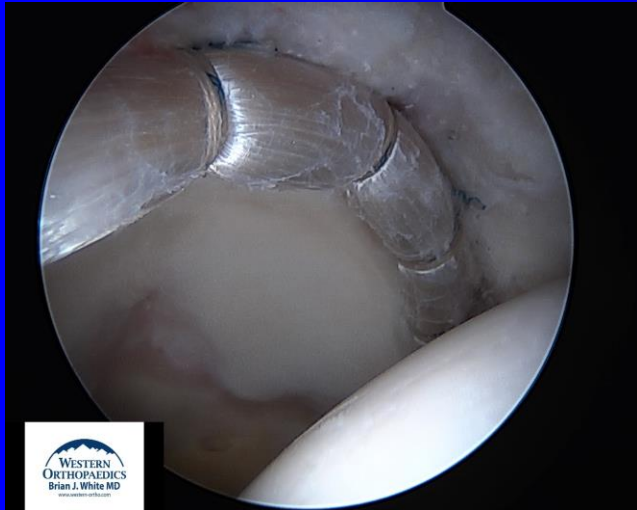
* IT band is soft tissue on the side of the thigh

Labral Reconstruction



This is a very powerful procedure in which painful labral tissue can be replaced with a graft that can restore the function of the labrum but should never feel pain.

An Ideal Solution



- Painful labral tissue is removed
- Graft material should always be aneural and never be able to perceive pain
- Complete Circumferential Reconstruction restores normal anatomy and function
 - My graft length is 11 ½ - 15 cm
- I have performed over 4,000 reconstructions to date.

Conclusions from Literature

- Hip arthroscopy can significantly improve patient's symptoms and function
- Labral Preservation works better than removing or debriding the torn Labrum
- Labral Reconstruction is a better procedure in my hands than Labral Repair
- Must treat the FAI or dysplasia, not just the labrum. You have to treat the problem which caused the labrum to tear. The Ball and Cup must be meticulously reshaped.
- Uncertain if Hip Arthroscopy prevents future arthritis. It certainly delays it by improving the hip mechanics and making a new labrum but 10, 20, and 30 year studies are not yet available.

I Do Not Repair the Labrum. Why not?

- The repair technique damages the native Labrum's blood supply
- The Labrum is often too damaged for an adequate repair
- The repaired labrum can often re-tear and still feel pain
- The need for a second surgery with a Labral Repair is simply too high

My Indications and literature

- I am very academic despite being in private practice.
- ALL of my hip arthroscopies have been included in a database since July 2009.
 - This has allowed me to objectively validate and improve my technique.
- I lecture internationally, conduct studies to advance the field, and teach surgeons from around the world how to perform my Labral Reconstruction technique.

My Key Labral Reconstruction Studies:

- Revision Study: How do you treat someone who has failed a previous hip arthroscopy?
- Direct comparison of Labral Repair to Reconstruction- Bilateral hip scope study
- Patients Over the age of 40 Study

*I will summarize these in the following slides, but the complete papers are available on my website under the Patient and Surgeon Education sections.

“Revision Arthroscopic Acetabular Labral Treatment: Repair or Reconstruct?”

- Brian J. White MD, Julie Peterson, Mackenzie Herzog
- 14 Re-Repairs (50% failure)
- 90 Reconstructions (12% failure)
- Over 92% fu, Minimum of 2 years

Arthroscopy. Volume 32, No. 12. December 2016. pp 2513-2520.

Revision Labral Re-Repair was 4.1 times more likely to fail than Labral Reconstruction

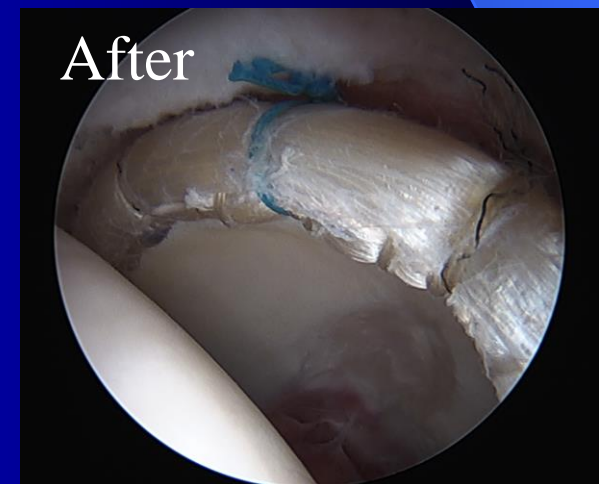
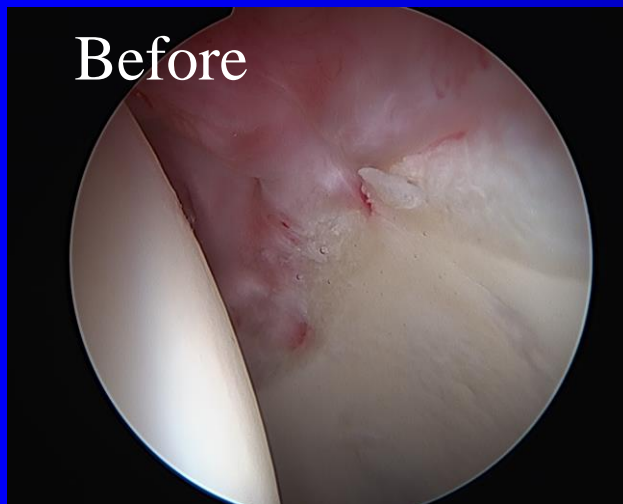
50% Failure with Repairing the Labrum again

12% Failure with the Reconstruction

Complete Circumferential Reconstructions were
better than the Shorter Segmental Grafts

Value of this study

- Largest study of Revision Hip Scopes published to date
- Considerably Lower Failure Rate with Reconstructions vs. Re-repair
 - 12% vs 50%...
- Objectively validates Labral Reconstruction as the Standard for a failed previous labral repair



“Bilateral Hip Arthroscopy: Direct Comparison of Primary Labral Repair and Primary Labral Reconstruction”

- Surgeries on Both Hips by me, only variable was the Labral Treatment: Repair or Reconstruction
- Minimum 2 year follow-up
- 29 patients
- 100% follow up

Arthroscopy. Vol 34, No 2. Feb 2018: pp 433-440.

Repair vs Reconstruction: Conclusions

- No Reconstructions failed
- 31% (9 of 29) of patients' REPAIR Side failed and they elected to have a 3rd surgery with me to convert their failed labral repair to a labral reconstruction. Since publication more have failed on their repair side.
- Labral Reconstruction was simply a better, more predictable operation that was significantly less likely to fail.

What About Patient Age Above 40?

- Several published papers from other institutions have shown nearly a 25% - 35% failure rate in this age group with labral repair and a high rate of conversion to Total Hip Replacement
- This simply has not been my experience with Labral Reconstruction...

“Hip arthroscopy in patients over 40: Greater success with Labral Reconstruction compared to Labral Repair”

- 316 hips were included
- Comparison of:
 - Over 40 with Labral Repair (93)
 - Over 40 with Labral Reconstruction (158)
 - 30-39 with Reconstruction as a control (117)
- Over 86% fu minimum of 2 years

Arthroscopy. Vol 36, No 8. Aug 2020: pp 2137-44

Results and Conclusions:

- No significant difference between the 2 Labral Reconstruction groups- 7% failure
 - 4% conversion rate to THA
 - Avg HHS improvement: 37
- Labral Repairs Failed in 21%

***** Labral Repairs were 3.29 times more likely to fail than Reconstructions in Patients over the age of 40 ***.** 95% CI, p=.02

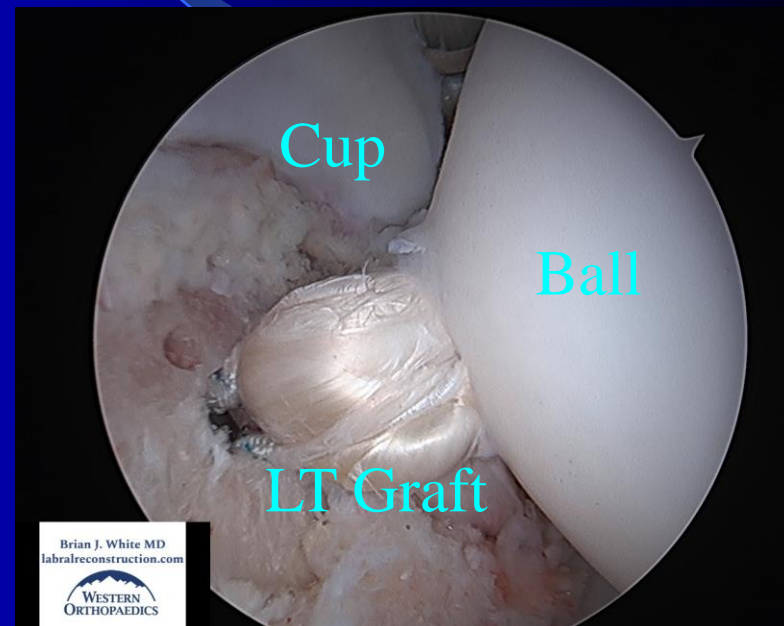
Age is Clearly Not the Issue...It is most likely the Labral quality that does not heal with labral repair in older patients.

Ligamentum Teres Reconstruction

- The ligamentum teres is a connection between the ball and the cup
- It can provide significant stability in patients who have an unstable hip or have dislocated their hip before and have torn this ligament
- It is helpful in patients with Ehrlor Danlos Syndrome and sometimes in patients who have a borderline low volume cup and are unstable
- The need for this operation is determined during surgery when the hip is unstable and the LT is deficient.

Uses for the Ligamentum Teres Reconstruction

- Unstable hip joint which is often seen with:
 - Ehrlor Danlos Syndrome
 - Low Volume Cup
 - Ligamentum Teres deficiency from previous dislocation or subluxation of the hip
- Look at it as a “Seat Belt” between the ball and the cup

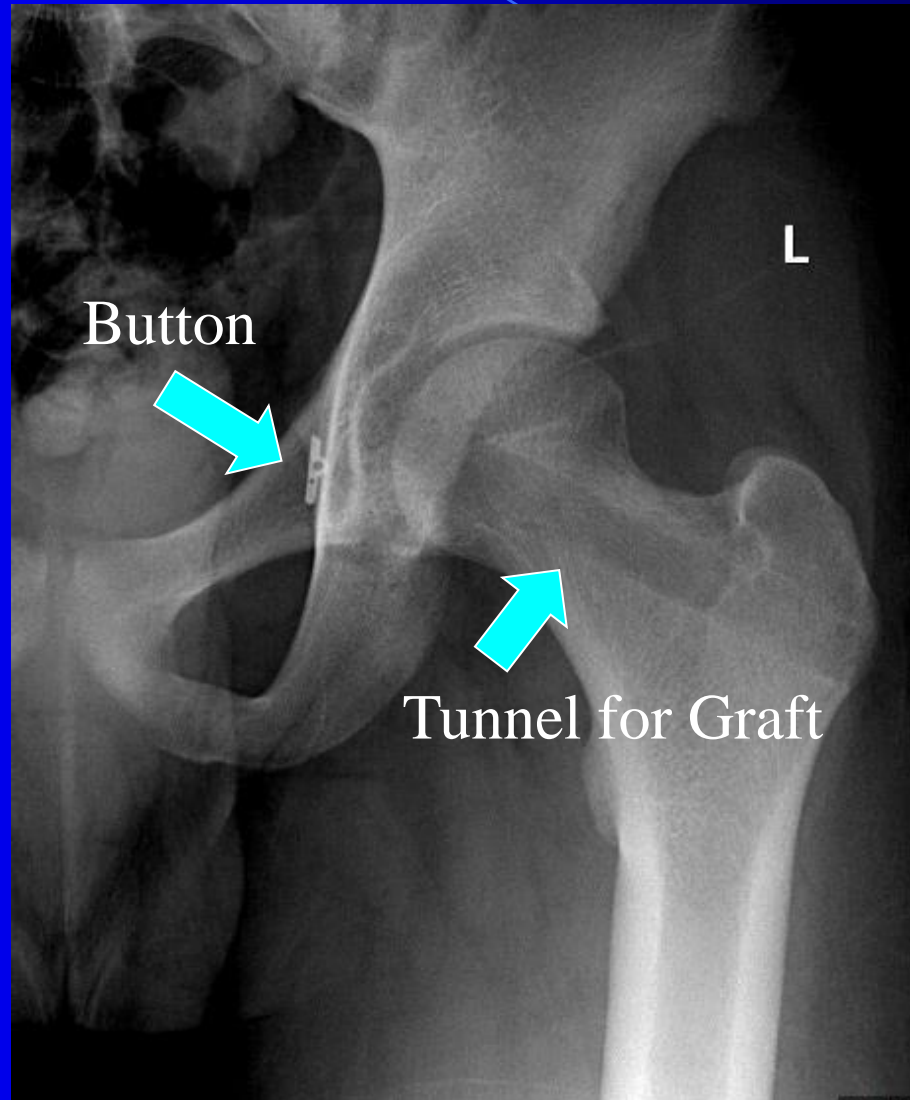


How is the Ligamentum Teres Reconstructed?

- A tunnel is drilled down the femoral neck to the center of the femoral head
- A button is used to fix the Graft on the Cup side
- A plastic screw (PEEK) is used to fix the graft on the femoral side
- 20% Weight bearing with crutches for 6 weeks instead of 4 weeks.
- No brace is used or required

LT Reconstruction X-Ray

This operation has been performed for over a decade in England



Experience Matters.

- This is a technically challenging operation and my results are not easy to reproduce.
- My Milestones:
 - 3,000th Labral Reconstruction December 2019
 - 4,000th Hip Arthroscopy May 2020
- I perform over 400 Labral Reconstructions per year
 - Over 100 are for people who have failed a labral repair from another surgeon (Revisions)

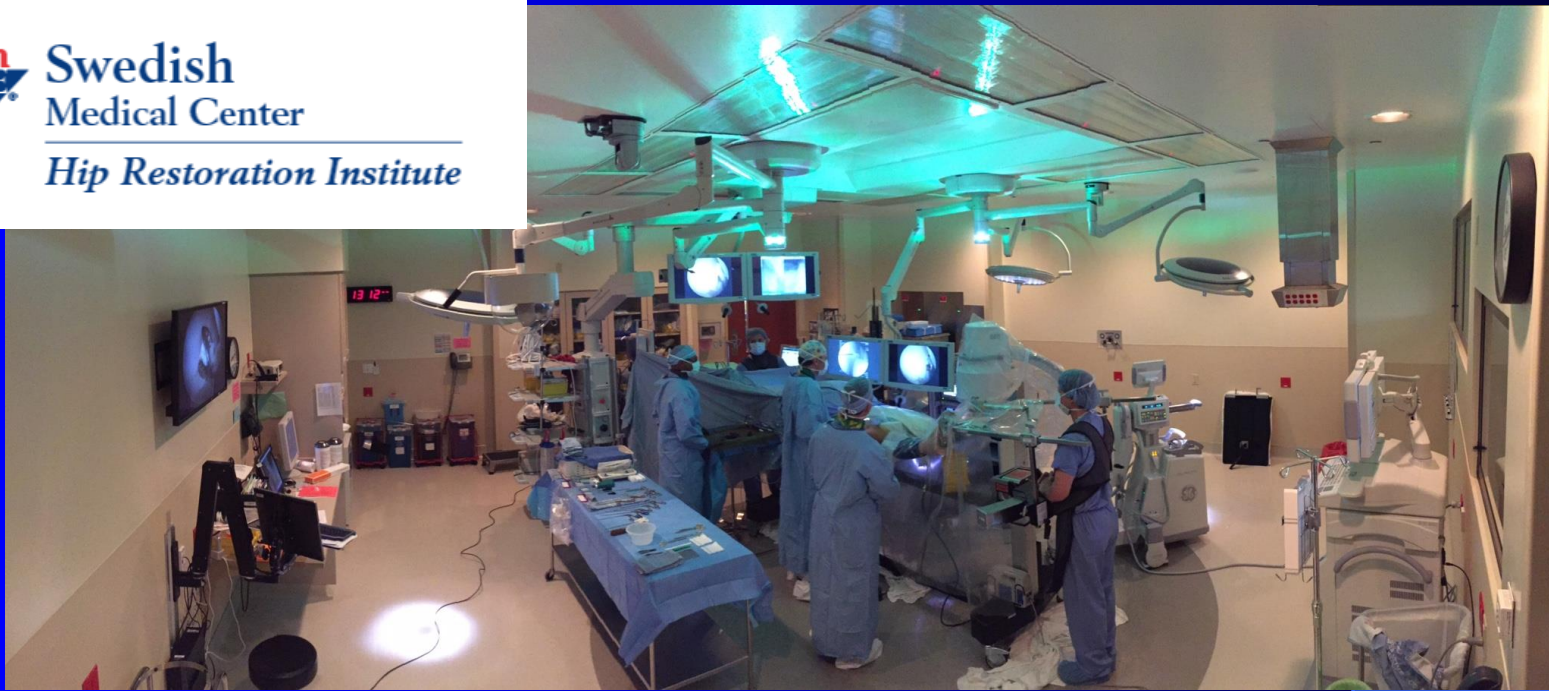What to Expect

- Overnight Stay in Hospital
 - All surgeries are performed at Swedish Hospital
 - I do not like surgery centers for this operation as I feel it is too rushed to discharge you the same day.
- Anaesthesia is General combined with:
 - Spinal, Quadratus Lumborum and a PENG block
 - These blocks reduce the amount of narcotic pain medications required during and after surgery
- Catheter is placed in your bladder while you are asleep and is removed the next morning
- Outpatient Physical Therapy
 - Initiated 3-5 days after surgery, lasts for 6-8 months
 - Our office will help you choose your therapist if you were not referred by one to me



Swedish
Medical Center

Hip Restoration Institute



- This is one of my two Operating Rooms at Swedish Medical Center

- State of the art OR specifically built for Hip Arthroscopy and can broadcast surgeries around the world to teach other surgeons
- The Hip Restoration Institute at Swedish Hospital is dedicated to the highest level of patient care, research and advancing the field of hip arthroscopy

After Surgery

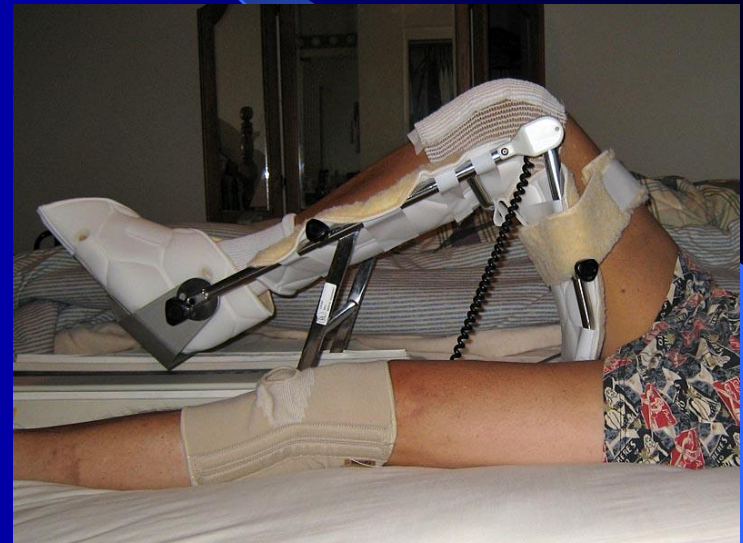
- White Boots to keep your feet straight after surgery
 - This will be provided to you in the OR
- Ice Machine to reduce swelling
- Compression sleeves to prevent blood clots
- Crutches: you can get them before or they will be provided at the hospital

Venapro



CPM or Bending Machine

- Slowly moves the hip after surgery to prevent scar tissue and reduce swelling and muscle spasms
- Used for 2-4 hours per day for 2 wks
- If a microfracture procedure was performed: 6-8 hrs/day for 6 wks
- Should not exceed 70 degrees of Flexion
- Can be worn at night



(if you are sitting upright the machine may be bending your hip more than 70 degrees)

Driving?

- In general, I recommend waiting until you feel safe to begin driving again. Some general guidelines are:
 - Right sided surgery usually takes a little longer to return safely (6 weeks based on the literature)
 - I recommend waiting until you are almost off crutches and off narcotic pain medications
 - Usually this takes roughly 3-6 weeks

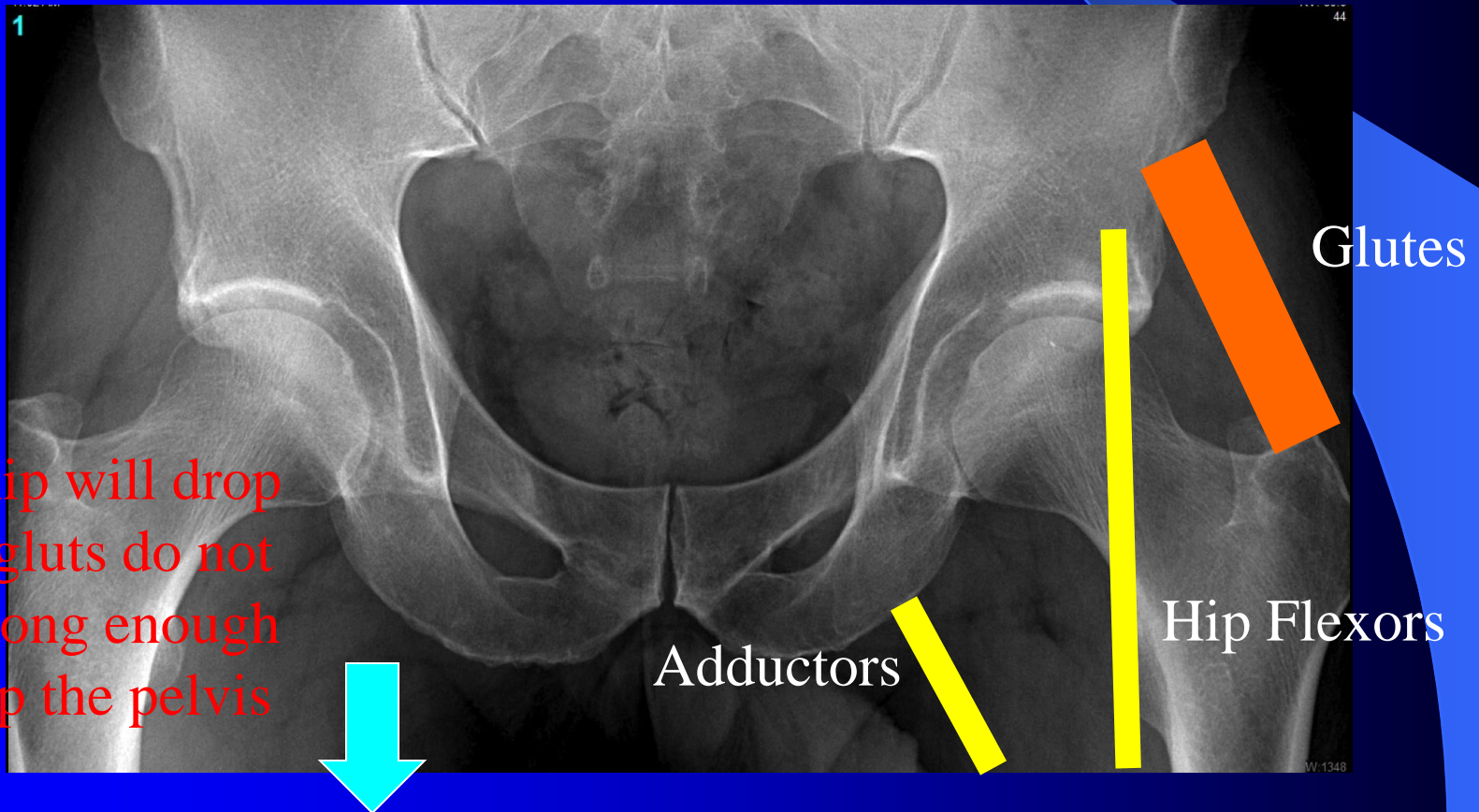
Return to Work?

- For the most part this is determined by the nature of your job
 - For desk or sedentary work: 2-4 weeks
 - Manual/Heavy work: 4-6 months
 - School as a student: 1-2 weeks
- Our office will assist with any paperwork necessary for your employer

Rehabilitation

- The hip is a more complex joint than the shoulder and knee.
- Crutches for 4 wks with partial weightbearing (6 wks if microfx performed)
- Foot stays straight up or forward for 2 wks to protect from a dislocation (White boots help with this)
- ****Slow with Hip Flexors****
 - **Hip Flexor Tendinitis** is a devastating, preventable complication with no cure and is the result of **inappropriate activity by you** during your recovery.
- Return to full sport is about 6 mos.

The Glutes are the key to rehabilitation. They must get strong so they automatically support and level the pelvis so that it does not dip with walking. This takes time and hard work with your Physical Therapist. If this does not occur before you become too active it will create pain and tendinitis in the Hip Flexor and Adductor and you will not be happy with your function.



Expected Timeline for Recovery

- 1 week: Patients are independent, have started Physical Therapy and are nearly off pain medication
- 6-8 weeks: Resuming normal function but sore at the end of the day
- 3-4 months: Physical Therapy more intense and fun. Feeling more normal for everyday activity.
- 6+months: Gradual return to full sport and activity. Amount of time to full recovery dependant on duration and severity of preoperative symptoms

Months 2-5

- This is the mental phase of recovery.
- Some days can be great, some can be very hard.
- It is very easy to over do it without meaning to.
- The key is to remain patient, listen to your Physical Therapist, and get your Gluteus Medius strong.

My Commitment

- When a patient decides to have surgery with me, I take that responsibility very seriously. I put everything I have into every surgery that I perform to ensure that my patients have the best possible outcome.

Thank you

- I hope this has allowed you to better understand your diagnosis and what hip arthroscopy can offer you for your condition. Please feel free to call us if you have any further questions.

