

Revision Arthroscopic Acetabular Labral Treatment: Repair or Reconstruct?



Brian J. White, M.D., Julie Patterson, B.S., R.N., and Mackenzie M. Herzog, M.P.H.

Purpose: To compare the outcome of labral repair versus labral reconstruction in patients presenting to a single surgeon for revision hip arthroscopy following previous labral treatment. **Methods:** Patients who underwent revision labral repair or labral reconstruction using iliotibial band allograft, after previous labral debridement or repair, between 2009 and 2013 were identified. Hips that underwent revision labral reconstruction were further stratified into 2 graft groups (freeze-dried vs frozen allograft). Exclusion criteria were age <16 years, previous open hip surgery, or previous labral reconstruction. Failure was defined by subsequent intra-articular hip surgery. **Results:** 113 hips (15 repair, 98 reconstruction) met the inclusion criteria. Patients who underwent revision labral repair were younger than patients who underwent revision labral reconstruction (27.8 years vs 34.6 years; $P = .02$). Follow-up was obtained from 14 (93%) labral repairs at an average of 4.7 years postoperation (range: 2.0-6.0 years) and 90 (92%) labral reconstructions at an average of 2.4 years postoperation (range: 2.0-4.0 years). Seven of 14 (50%) labral repair hips failed compared with 11/90 (12%) labral reconstruction hips ($P < .01$). Six of 61 (10%) frozen allografts failed compared with 5/29 (17%) freeze-dried allografts ($P = .32$). Patients who underwent revision labral repair were 4.1 (95% confidence interval 1.9, 8.8) times more likely to fail than patients who underwent revision labral reconstruction. **Conclusions:** Patients who underwent revision labral repair following previous repair or debridement were 2.6 times more likely to fail than patients who underwent revision labral reconstruction, controlling for calendar time. In addition, revision labral reconstruction with frozen allograft had lower propensity of failure than freeze-dried allograft. However, there was no statistically significant difference in patient-reported outcome scores between the 2 groups. Based on these results, complete labral reconstruction with longer, nonsegmental graft led to a lower failure rate in this study population and can be considered for treatment of patients presenting for revision labral treatment. **Level of Evidence:** Level III, retrospective comparative study.

Over the past decade, there has been immense innovation in hip arthroscopy, and new surgical techniques to treat labral pathology have been

continuously developed and improved. These procedures have progressed from the original labral debridement procedure¹ to more recent labral-preserving procedures, such as arthroscopic labral repair² and arthroscopic labral reconstruction.^{3,4}

Outcomes following hip arthroscopy have shown promising results, particularly among patients who undergo labral-preserving procedures. A prospective study of patient-reported outcomes following primary arthroscopic labral repair among 38 hips found that 4 hips (11%) required revision arthroscopy at a mean of 10 months postoperatively, and the mean improvement in Modified Harris Hip Score (MHHS) was 18.9 points, from 70.5 points preoperatively to 89.4 points at 2-year follow-up.⁵ Another study compared 50 hips that underwent labral refixation to 44 hips that underwent labral debridement and found that at a mean follow-up of 42 months, patients who had labral refixation had significantly higher patient-reported outcome scores.⁶ In addition, the authors reported that 4 hips (9.1%) in the labral debridement group and 4 hips (8.0%) in the labral refixation group failed treatment, where

From Western Orthopaedics (B.J.W.), Denver, Colorado; Centura Health Research Center (J.P.), Denver, Colorado; and Professional Research Institute for Sports Medicine, LLC (M.M.H.), Chapel Hill, North Carolina, U.S.A.

The authors report the following potential conflict of interest or source of funding: B.J.W. receives support from Western Orthopaedics; from Smith & Nephew for hip arthroscopy education; and for education and product development for hip arthroscopy with Smith & Nephew, Biomet, and Conmed Linvatec. M.M.H. received consulting fee through his consulting company Professional Research Institute for Sports Medicine (PRISM) from Western Orthopaedics for work on this project; receives employment support from Professional Research Institute for Sports Medicine (PRISM), University of North Carolina at Chapel Hill, Children's Healthcare of Atlanta; and is the owner of the consulting company Professional Research Institute for Sports Medicine.

Received February 11, 2016; accepted July 18, 2016.

Address correspondence to Brian J. White, M.D., Western Orthopaedics, 1830 Franklin Street, Suite 450, Denver, CO 80218-1217, U.S.A. E-mail: prismresearchconsulting@gmail.com

© 2016 by the Arthroscopy Association of North America
0749-8063/16120/\$36.00

<http://dx.doi.org/10.1016/j.arthro.2016.07.024>

failure was defined as MHHS <70 or subsequent intra-articular surgery.⁶

Despite the promising patient-reported outcomes following arthroscopic labral treatment, there remains a subset of patients who fail the initial hip arthroscopy and require a revision procedure. A recent systematic review of outcomes following all types of hip arthroscopy among 6,134 patients found that 6.4% of surgeries went on to reoperation.⁷ Another systematic review of indications and outcomes for revision hip arthroscopy found that 77.9% of revision operations included labral treatment.⁸ Although most patients reported improvement in symptoms following revision hip arthroscopy, 14.6% of patients failed the revision hip arthroscopy and moved on to a third procedure.⁸

Given the continual growth and development in hip arthroscopy techniques, there are now several options for labral treatment in the revision hip arthroscopy setting, and the optimal technique remains widely debated. Techniques that do not preserve the labral tissue have largely fallen out of favor, but both revision labral repair⁹ and revision labral reconstruction¹⁰ present viable options for treatment of recurrent labral pathology. The purpose of this study was to compare the outcome of labral repair versus labral reconstruction in patients presenting to a single surgeon for revision hip arthroscopy following previous labral treatment. The hypothesis was that patients who present for revision hip arthroscopy and undergo acetabular labral reconstruction will have a lower failure rate and improved patient-reported outcomes compared with patients who undergo acetabular labral repair.

Methods

Participant Selection

This was an institutional review board–approved retrospective cohort study of all patients who underwent revision arthroscopic labral treatment of the hip by a single surgeon (B.J.W.) between September 2009 and December 2013. During the study period, all patients who were scheduled to undergo arthroscopic labral treatment were prospectively enrolled into a hip registry that included a preoperative subjective questionnaire and postoperative follow-up questionnaire at the 3-month, 6-month, 9-month, and annual follow-up visits. All hips that underwent arthroscopic labral repair or labral reconstruction and had previous labral repair or labral debridement were selected from the registry for inclusion in this retrospective cohort. There were 125 hips that met the inclusion criteria for the study. Patients who were <16 years of age ($n = 2$ hips), hips that had a previous labral reconstruction ($n = 2$), or hips that had a previous open surgical hip dislocation ($n = 8$) were excluded, leaving 113 hips among 104 patients.

Diagnosis of labral pathology was made by clinical examination and magnetic resonance imaging. Revision hip arthroscopy was indicated if the patient had a magnetic resonance imaging–confirmed labral retear or high clinical suspicion for a retear (including positive diagnostic injection), had residual or new hip pain that was reproduced with anterior impingement maneuver, failed nonoperative treatment for the current symptoms, and had preserved joint space (Tonnis grade 0 or 1). Patients who met the indications for revision hip arthroscopy were treated with either arthroscopic labral repair or labral reconstruction using iliotibial band allograft. The treatment choice was generally made based on a shift in the lead surgeon's practice. Patients who underwent revision hip arthroscopy with labral repair were treated from September 2009 to December 2011, and patients who underwent revision hip arthroscopy with labral reconstruction were treated from April 2011 to December 2013. In 2012, the lead surgeon began only performing arthroscopic labral reconstruction in the revision setting due to an unacceptable failure rate with the revision repairs. Between April 2011 and December 2011, indications for labral reconstruction versus labral repair were labral tissue >8 mm or <2 to 3 mm or an irreparable labral tear. Hips that were included in the cohort were separated into 2 exposure groups: revision labral repair and revision labral reconstruction.

Hips that underwent revision labral reconstruction were further stratified into 2 groups for each graft type, including freeze-dried allograft and frozen allograft. Hips treated from April 2011 to April 2012 using labral reconstruction were exclusively treated with freeze-dried allograft; however, the lead surgeon began transitioning to frozen allograft after April 2012. Beginning in December 2012, the lead author transitioned to exclusive frozen allograft use primarily because of graft availability, in addition to the potential benefits of longer grafts, and similarity to native tissue.

Data Collection

Data were collected subjectively at the time of the preoperative visit for the index procedure and postoperatively at the time of most recent follow-up by a research assistant either in the clinic or by mail. Data were also collected objectively from the clinical examination visits (typically through postoperative year 1) and at the time of surgery. Subjective questionnaire data included the Modified Harris Hip Score (MHHS),¹¹ the Lower Extremity Function Score (LEFS),¹² a visual analog scale for average pain at rest, average pain with daily activities, and average pain with athletic activities. Although the LEFS has not been validated for assessment of nonarthritic hip conditions, it has been shown to be valid, reliable, and responsive for use in patients with hip osteoarthritis¹³ and has been used for

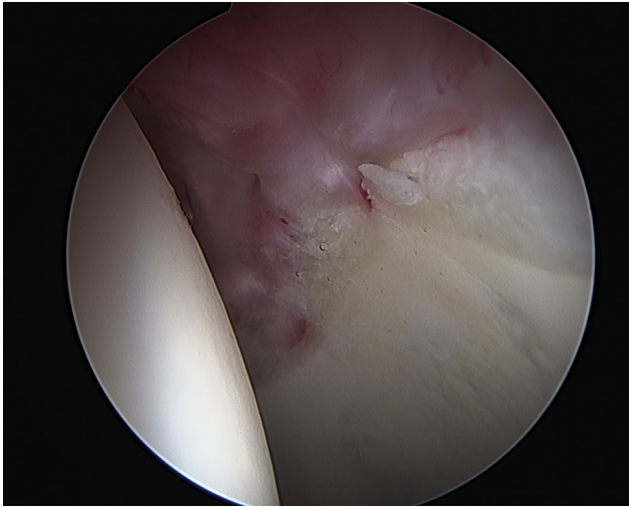


Fig 1. Arthroscopic view from the anterolateral portal of a left hip showing re-torn previous 2 anchor labral repair.

assessment of outcomes in patients undergoing treatment of nonarthritic hip pathology.^{14,15} In addition, it assesses an important domain of physical activities of daily living that the study team felt was appropriate and ideal to measure patient-reported outcome in this population. Patient-rated overall satisfaction on a scale from 1 to 10 (10, extremely satisfied) was also collected at the most recent follow-up. The outcome score was only calculated if it was completed in its entirety. If more than 1 outcome score (MHHS, LEFS, or visual analog scale) was missing, the patient was considered to have incomplete follow-up and was not included in the analysis of follow-up data.

The lead surgeon recorded all objective data, including clinical, radiographic, and surgical data points. The number of previous procedures performed on the ipsilateral hip and the type of previous labral treatment, which were reported to the surgeon by the patient, were also recorded. Surgical data included assessment of the femoral head and acetabular cartilage, labral quality, femoroacetabular impingement, and capsular quality. Any concomitant procedures at the time of the index procedure were also recorded. Failures were defined as the need for revision surgery on the ipsilateral hip.

Surgical Technique

The surgical techniques used for hips with previous labral repair or debridement (Figs 1 and 2) were those that were previously reported for arthroscopic labral repair² and arthroscopic labral reconstruction.⁴ Briefly, for the revision labral repair, the technique involved standard hip arthroscopy exposure, separating the labral tissue from the capsule, removing adhesions, and repairing the labrum with circumferential sutures. For revision labral reconstruction, all procedures were complete reconstruction, not segmental. For the

purposes of this manuscript, we consider longer grafts that span the complete area of the native labrum to be complete reconstructions while reconstructions that leave residual labral tissue intact to be segmental. The technique involved working on the central compartment whereas the joint was reduced in the peripheral compartment. This allowed for visualization of the anteroinferior joint and dissection from a normal capsulolabral junction into the scar to separate the capsule from the labrum, which allowed for preservation of the hip capsule and full labral and scar resection. Freeze-dried or frozen iliotibial band allograft was used to create a graft that was overestimated by 1 cm, which prevents the graft from being too short (Fig 3). The goal of the labral reconstruction is to provide a perfect seal between the reconstructed labrum and the femoral head (Fig 4). For both revision procedures, bony work to address residual femoroacetabular impingement was performed when necessary.

Postoperative Management

Patients who underwent revision labral repair and revision labral reconstruction followed a similar postoperative rehabilitation program. They began supervised physical therapy during the week following surgery and were limited to 30% weight bearing for 4 weeks following the procedure. Patients who underwent concomitant microfracture were limited to 20% weight bearing for an additional 2 weeks.

Statistical Analysis

Statistical analysis was conducted using Statistical Analysis Software 9.4 (SAS Institute, Cary, NC). Descriptive statistics were calculated overall and stratified by group. For comparisons of demographic data

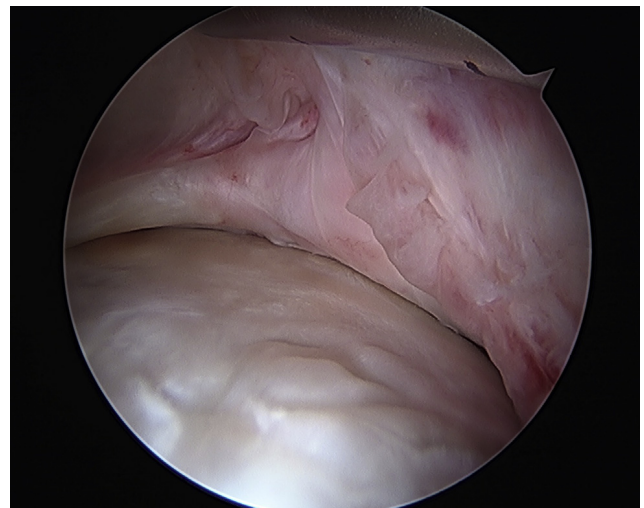


Fig 2. Arthroscopic view of the same left hip from the anterolateral portal with the hip reduced. The re-torn labrum is severely inflamed and scarred into the hip capsule.

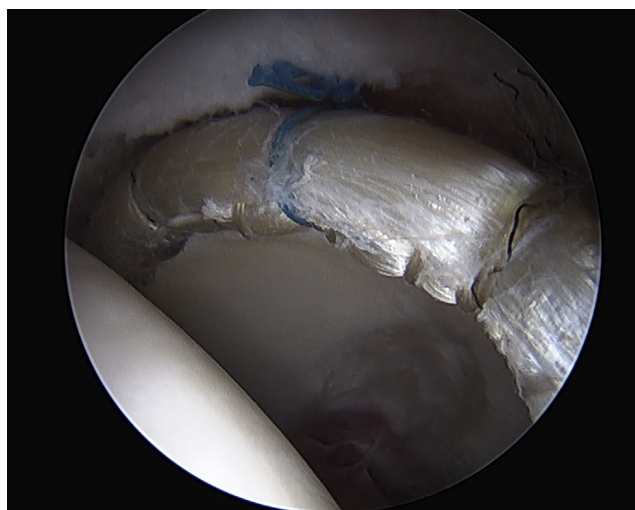


Fig 3. Arthroscopic view of the same left hip after 10 cm labral reconstruction with frozen fascia lata allograft fixed with 8 anchors viewed from the anterolateral portal.

involving continuous variables, Wilcoxon rank sum test was used because of the small sample size in the repair group. For comparisons involving dichotomous variables, Fisher exact test was used.

Multivariable log-binomial regression was used to assess the association between group (revision repair vs revision reconstruction) and failure, which was defined as any subsequent ipsilateral, intra-articular hip surgery. Revision repair was compared to revision reconstruction overall and also to each graft type (freeze-dried or frozen allograft). The crude risk ratio and 95% confidence interval (CI) were calculated. A model including calendar time was also used to calculate an adjusted risk ratio and 95% CI. Although there are many variables that may be associated with the outcomes of interest (failure and patient-reported outcome scores), such as concomitant procedures or other patient characteristics, very few are also associated with the exposure of interest for this study (choice of revision labral procedure). In fact, over the study period, the motivation for performing one procedure versus the other was driven almost exclusively by calendar time, which also may affect the propensity for failure due to learning curve and/or differential follow-up time. Therefore, because a true confounder must be associated with both the exposure and outcome of interest, calendar time was adjusted for in the analysis, to attempt to reduce confounding bias.

Comparison of subjective outcome scores was performed for those patients who did not fail. For comparison between the revision repair and revision reconstruction groups, Wilcoxon rank sum test was used for all subjective outcome scores. Statistical significance was determined using 2-sided tests and a 95% significance level.

Results

Of the 113 hips that met the inclusion criteria, 15 hips had a revision repair and 98 hips had a revision reconstruction. The mean age at the time of surgery was 34 years (range: 16-60 years). The demographic and surgical information by group for the patients included in the cohort is listed in [Table 1](#). Among hips that underwent revision reconstruction, the mean graft length was 8.0 cm (range: 4.2-11.0 cm). Twenty-nine (30%) of the reconstructed hips had a freeze-dried allograft and 69 (70%) had a frozen allograft. There was a significant difference in graft length between the freeze-dried and frozen allografts (6.5 ± 1.5 vs 8.6 ± 0.7 cm, respectively; $P < .0001$).

Follow-up was available for 104 hips (92%) at a mean of 2.6 years postoperatively (range: 2.0-6.0 years). Nine hips (8%) were lost to follow-up or had incomplete follow-up data. Fourteen hips (93%) from the revision labral repair group completed follow-up at a mean of 4.7 years postoperatively (range: 2.0-6.0 years), and 90 hips (92%) from the revision labral reconstruction group completed follow-up at a mean of 2.4 years postoperatively (range: 2.0-4.0 years). All patients had a minimum of 2-year follow-up.

Overall, 18 hips (17%) failed treatment at a mean of 20.8 months postoperatively (range: 7.3-42.2 months). There was a statistically significant difference in failure rate between the revision labral repair group and the revision labral reconstruction group ($P < .01$). In the revision labral repair group, 7 hips (50%) failed at a mean of 17.0 months postoperatively (range: 7.3-30.4 months). In the revision labral reconstruction group, 11 hips (12%) failed at a mean of 23.6 months (range: 9.3-42.2 months). Within the labral reconstruction group, 6 of 61 (10%) frozen allografts failed

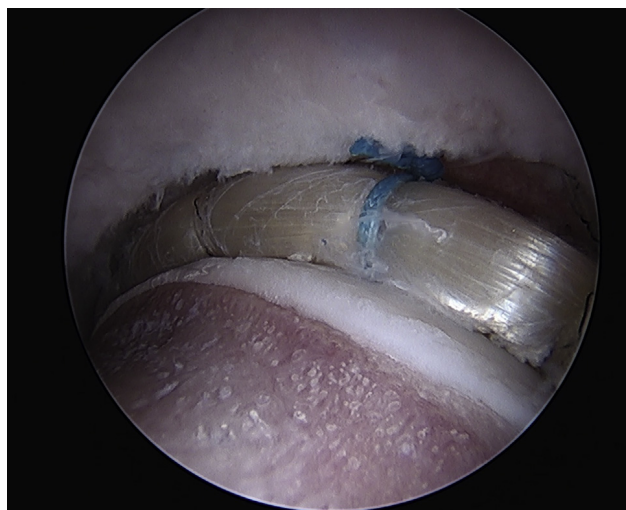


Fig 4. Arthroscopic view of the same left hip from the anterolateral portal. The hip is reduced showing an excellent seal between the labral reconstruction and the femoral head.

Table 1. Demographic and Operative Information for Patients Who Underwent Revision Arthroscopic Labral Treatment of the Hip, 2009-2013 (n = 113)

	Revision Labral Repair (n = 15)	Revision Labral Reconstruction (n = 98)	P Value
Gender			.55
Male	5 (33%)	26 (27%)	
Female	10 (67%)	72 (73%)	
Age, years	27.8 ± 11.8	34.6 ± 10.2	.02
Number of previous surgeries	1.0 ± 0.0	1.1 ± 0.3	.15
Previous labral debridement*	3 (33%)	16 (19%)	.39
Acetabular cartilage status			
Normal	8 (53%)	22 (23%)	.02
Grade 1	3 (20%)	2 (2%)	.02
Grade 2	2 (13%)	46 (48%)	.02
Grade 3	2 (13%)	19 (20%)	.73
Grade 4	0 (0%)	7 (7%)	.59
Femoral head cartilage status			
Normal	11 (73%)	68 (69%)	>.99
Grade 1	2 (13%)	8 (8%)	.62
Grade 2	2 (13%)	14 (14%)	>.99
Grade 3	0 (0%)	8 (8%)	.59
Grade 4	0 (0%)	0 (0%)	>.99
Concomitant procedures			
Femoral osteoplasty for cam	4 (27%)	6 (6%)	<.01
Acetabular rim trimming for pincer	2 (13%)	12 (12%)	.28
Treatment of combined FAI	1 (7%)	68 (69%)	<.01
Microfracture	0 (0%)	6 (6%)	>.99
Chondroplasty	2 (13%)	41 (42%)	.04
Psoas release	3 (20%)	28 (29%)	.76

NOTE. Data shown as n (%) or mean ± standard deviation. FAI, femoroacetabular impingement. *Data available for 92 hips (81%).

compared with 5 of 29 (17%) freeze-dried allografts ($P = .32$).

Hips that underwent revision labral repair were 4.1 (95% CI 1.9, 8.8) times more likely to fail than hips that underwent revision labral reconstruction. When adjusting for calendar time, hips that underwent revision labral repair were 2.6 (95% CI 0.6, 12.3) times more likely to fail than hips that underwent revision labral reconstruction. Among those that failed the index procedure, 10 underwent revision labral reconstruction, 6 converted to total hip arthroplasty, 1 underwent revision labral debridement and treatment of recurrent femoroacetabular impingement, and 1 underwent treatment at an outside institution and specific details were not available.

Among those patients who did not fail treatment (n = 86 hips), there was no statistically significant

difference in patient-reported outcome scores between the 2 groups (Table 2). However, patients who underwent revision labral reconstruction had a slightly greater change in outcome scores from preoperative to postoperative on average, although this was not statistically significant. For example, patients in the revision labral reconstruction group had an average 31.7-point change in MHHS and a 25.7-point change in the LEFS compared with a 28.0-point change in the MHHS and a 20.8-point change in the LEFS among the revision labral repair group. Those who underwent labral reconstruction also reported slightly greater decrease in visual analog scale pain score (−3.6 vs −2.8) and slightly higher patient satisfaction (8.4 vs 7.6).

Discussion

The results of this retrospective cohort study of patients treated by a single surgeon suggest that patients who undergo revision hip arthroscopy with labral repair were 4.1 times more likely to fail treatment than those who undergo labral reconstruction, where failure is defined as subsequent intra-articular hip surgery. Hips that underwent revision labral repair were still more likely to fail than hips that underwent revision labral reconstruction in this study (2.6 times more likely to fail) even after adjusting for calendar time in an attempt to adjust for learning curve and differential follow-up time. These findings confirmed our initial hypothesis regarding reduced propensity for failure among patients who undergo revision labral reconstruction. Among those hips that failed the revision, hips that underwent revision labral repair failed earlier than hips that underwent revision reconstruction, although not

Table 2. Comparison of Patient-Reported Outcomes for Patients Who Underwent Revision Arthroscopic Labral Treatment of the Hip From 2009 to 2013 and Did Not Fail Treatment at Mean 2.6 Years Follow-up (n = 86)

	Revision Labral Repair (n = 7)	Revision Labral Reconstruction (n = 79)	P Value
MHHS			
Preoperative	56.1 ± 9.1	49.3 ± 16.7	.31
Postoperative	84.1 ± 18.9	81.2 ± 20.7	.74
Change	28.0 ± 18.9	31.7 ± 22.4	.67
LEFS			
Preoperative	49.7 ± 16.0	36.8 ± 16.4	.24
Postoperative	69.6 ± 13.8	62.6 ± 17.0	.23
Change	20.7 ± 21.9	25.7 ± 19.7	.71
VAS score			
Preoperative	5.1 ± 2.2	6.6 ± 1.7	.06
Postoperative	2.3 ± 5.1	3.0 ± 2.1	.45
Change	−2.8 ± 2.8	−3.6 ± 2.5	.43
Patient satisfaction	7.6 ± 3.6	8.4 ± 2.3	.90

NOTE. Data shown as mean ± standard deviation. LEFS, Lower Extremity Function Score; MHHS, Modified Harris Hip Score; VAS, visual analog scale.

statistically significant (17.0 vs 24.5 months; $P = .16$). Contrary to our original hypothesis, we found no statistically significant difference in patient-reported outcome scores among those who do not fail treatment.

Furthermore, revision labral reconstruction with frozen allograft resulted in a lower risk of failure than freeze-dried allograft reconstruction, although not statistically significant ($P = .32$). Although this may suggest slight superiority of frozen allograft compared with freeze-dried allograft, it is also possible that these results are affected by temporality of graft use. Labral reconstruction is a very new, technically demanding, hip arthroscopy technique. Hips treated with freeze-dried allograft had arthroscopy from April 2011 to April 2012, whereas hips treated with frozen allograft had arthroscopy after April 2012. Therefore, it is possible that the difference in failure rates between the 2 graft type groups may be influenced by overcoming the learning curve for this procedure. In addition, freeze-dried allografts were significantly shorter than frozen allografts (6.5 ± 1.5 vs 8.6 ± 0.7 cm, respectively; $P < .0001$). Therefore, it is also possible that the difference in failure rate is influenced by transition to longer grafts and more complete, longer labral reconstructions, rather than the shorter, more segmental labral reconstructions with earlier techniques. Further research is needed to better understand optimal allograft type.

Although revision labral reconstruction provided superior results in terms of failure rate, there was relatively no difference in patient-reported outcome scores between the 2 groups for patients who did not fail treatment (Table 2). Although the failure rate for hips that underwent revision labral repair was high at 50%, those hips that survived had a relatively equivalent outcome to those that survived the revision labral reconstruction. The fact that patient-reported outcome scores are relatively equal between the groups, despite the significant difference in failure rate, suggests that there may be intra-articular characteristics that are necessary for a successful revision repair. For example, hips that survived treatment may have had adequate labral tissue remaining to maintain or restore the intra-articular pressure seal.^{16,17} Future research should identify preoperative and intraoperative predictors of success following revision labral repair to inform operative decision making; however, these criteria do not yet exist and the sample size in our study was too small to provide meaningful results.

Primary hip arthroscopy for labral pathology has shown promising early outcomes with a relatively low failure rate^{7,8}; however, when a patient presents with residual pain, symptoms, and/or disability following prior arthroscopic labral treatment, revision hip arthroscopy may be warranted. Revision labral reconstruction offers several advantages for restoring the anatomy of the native hip. First, this technique allows

for creation of a consistent graft size to ensure an adequate pressure seal can be restored and maintained.¹⁰ Aside from addressing labral pathology, labral reconstruction also allows for exposure of the entire acetabular rim following resection of the labrum to address any residual pincer impingement or acetabular cartilage damage that may not be otherwise appreciated.¹⁰ Furthermore, the graft should always remain aneural so it is ideal in the setting of chronic pain from failure of a previous arthroscopy. Finally, the results of this study suggest that revision labral reconstruction yields a significantly lower failure rate, particularly among those with frozen allograft and longer reconstructions, and equal patient-reported outcome scores to revision labral repair. In fact, hips that underwent revision labral reconstruction had slightly greater changes in scores from preoperative to postoperative. Therefore, labral reconstruction should be considered in the setting of revision hip arthroscopy for treatment of residual labral pathology.

Although technique comparisons for revision acetabular labral treatment are underreported, a few studies have assessed outcomes following revision hip arthroscopy. In 2014, Domb et al.¹⁸ reported clinical outcomes for 47 hips that underwent revision arthroscopy for a variety of intra-articular pathologies. Of the hips that had revision arthroscopy, 27 underwent labral debridement, 14 underwent labral repair, and 4 underwent labral reconstruction. Although only 4 hips underwent labral reconstruction, results of multiple regression analyses suggested that segmental labral defects treated with labral reconstruction were predictive of improved patient-reported outcome scores for the MHHS, the Non-Arthritic Hip Score, the Hip Outcome Score—Activities of Daily Living, and the Hip Outcome Score—Sport-Specific Subscale.¹⁸ Another study compared the outcomes of revision femoroacetabular impingement correction with concomitant intra-articular procedures to primary femoroacetabular impingement correction with concomitant intra-articular procedures and reported that hips that underwent labral repair or labral reconstruction had increased MHHS values postoperatively than hips that underwent labral debridement.¹⁹

In comparison to previous reports of patient outcomes following hip arthroscopy, the results of our study are comparable or better than previously reported revision hip arthroscopy outcomes. A recent study by Gupta et al.²⁰ reported a 15.8-point improvement in MHHS among all patients undergoing revision hip arthroscopy. In addition, a previous systematic review of revision hip arthroscopy outcomes found an average MHHS improvement of 19.3 points.⁸ Our study found a greater improvement in MHHS for both the revision labral reconstruction and revision labral repair groups of 31.7 points and 28.0 points, respectively.

Findings from our study, in addition to previous research findings, suggest that labral reconstruction may be the preferred method of labral treatment in the setting of revision hip arthroscopy. Labral reconstruction may provide superior outcomes, particularly in terms of failure rate, compared with labral repair when performed as a revision labral procedure. Further research on this topic is necessary to corroborate these findings.

Limitations

This was an observational study and is subject to the limitations of this type of study design. First, there is a possibility of unmeasured confounding variables; however, the authors carefully assessed potential confounding variables that may be associated with both the choice of procedure and the outcomes of interest and controlled for the one measured, known confounder (calendar time) in the statistical model for association between treatment group and failure. In addition, it is important to note that although the possibility remains that the 2 groups are different in respect to patient or surgery characteristics, the data suggest that patients in the revision labral reconstruction group actually had more characteristics associated with propensity for failure than the revision labral repair group. For example, hips that underwent revision labral reconstruction had slightly lower preoperative scores, on average, compared with hips that underwent revision labral repair, and patients were slightly older than patients who underwent revision labral repair. Hips in the revision labral reconstruction group also were more likely to have had multiple previous procedures, whereas no hip in the revision labral repair group had more than 1 previous procedure. Therefore, although the possibility remains for unmeasured confounding variables, the authors believe that the results provide an interesting association for increased probability of failure among hips that underwent revision labral repair in this cohort. Second, there is a small risk for response bias related to patient follow-up. Although the follow-up percentage was quite high (92%) and relatively balanced between the groups (92% and 93%), it remains possible that the outcome of the remaining hips could have changed the conclusion of the research study. However, follow-up was only missing from 11 hips in the reconstruction group and 1 hip in the repair group. Related to response bias, another criticism may be the differing lengths of follow-up between the 2 groups. Given that labral repairs were performed chronologically earlier in our series, hips in that group were eligible for longer follow-up (mean follow-up 4.7 vs 2.4 years). It is possible that with longer follow-up, hips may be more likely to require a revision procedure. However, the authors attempted to control for this potential confounder by including calendar time in the

statistical model. It is also important to note that the time from the index procedure to the re-revision was shorter among hips that had revision labral repair (17.0 vs 24.5 months). It is possible that longer follow-up may bring the proportion of hips that fail closer together, but the conclusion remains that revision labral repairs in this series were more likely to fail early. Finally, as with any research study, the findings of this analysis are only generalizable to patients with characteristics similar to those included in our patient population. Patients <16 years of age, those with previous open surgical dislocation surgery, and those with previous labral reconstruction were not included in this analysis, and other treatment options for recurrent labral pathology were not studied. Therefore, inference from this study cannot be extended to those populations. Furthermore, this study represents the experience of a single surgeon with regard to these hip arthroscopy techniques. The study was performed in a high-volume, hip specialty practice and is a technically demanding procedure that requires proficiency in hip arthroscopy techniques. Therefore, the results of this study may not be generalizable to other practices or patient populations.

Conclusion

Patients who underwent revision labral repair following previous repair or debridement were 2.6 times more likely to fail than patients who underwent revision labral reconstruction, controlling for calendar time. In addition, revision labral reconstruction with frozen allograft had lower propensity of failure than freeze-dried allograft. However, there was no statistically significant difference in patient-reported outcome scores between the 2 groups. Based on these results, complete labral reconstruction with longer, non-segmental graft led to a lower failure rate in this study population and can be considered for treatment of patients presenting for revision labral treatment.

References

1. Byrd JW. Hip arthroscopy utilizing the supine position. *Arthroscopy* 1994;10:275-280.
2. Kelly BT, Weiland DE, Schenker ML, Philippon MJ. Arthroscopic labral repair in the hip: Surgical technique and review of the literature. *Arthroscopy* 2005;21:1496-1504.
3. Philippon MJ, Briggs KK, Hay CJ, Kuppersmith DA, Dewing CB, Huang MJ. Arthroscopic labral reconstruction in the hip using iliotibial band autograft: Technique and early outcomes. *Arthroscopy* 2010;26:750-756.
4. White BJ, Herzog MM. Arthroscopic labral reconstruction of the hip using iliotibial band allograft and front-to-back fixation technique. *Arthrosc Tech* 2016;5:e89-e97.
5. Byrd JW, Jones KS. Primary repair of the acetabular labrum: Outcomes with 2 years' follow-up. *Arthroscopy* 2014;30:588-592.

6. Larson CM, Giveans MR, Stone RM. Arthroscopic debridement versus refixation of the acetabular labrum associated with femoroacetabular impingement: Mean 3.5-year follow-up. *Am J Sports Med* 2012;40:1015-1021.
7. Harris JD, McCormick FM, Abrams GD, et al. Complications and reoperations during and after hip arthroscopy: A systematic review of 92 studies and more than 6,000 patients. *Arthroscopy* 2013;29:589-595.
8. Sardana V, Philippon MJ, de Sa D, et al. Revision hip arthroscopy indications and outcomes: A systematic review. *Arthroscopy* 2015;31:2047-2055.
9. Philippon MJ, Schenker ML, Briggs KK, Koppersmith DA, Maxwell RB, Stubbs AJ. Revision hip arthroscopy. *Am J Sports Med* 2007;35:1918-1921.
10. White BJ, Stapleford AB, Hawkes TK, Finger MJ, Herzog MM. Allograft use in arthroscopic labral reconstruction of the hip with front-to-back fixation technique: Minimum 2-year follow-up. *Arthroscopy* 2016;32:26-32.
11. Byrd JW, Jones KS. Prospective analysis of hip arthroscopy with 2-year follow-up. *Arthroscopy* 2000;16:578-587.
12. Binkley JM, Stratford PW, Lott SA, Riddle DL. The Lower Extremity Functional Scale (LEFS): Scale development, measurement properties, and clinical application. North American Orthopaedic Rehabilitation Research Network. *Phys Ther* 1999;79:371-383.
13. Naal FD, Impellizzeri FM, Torka S, Wellauer V, Leunig M, von Eisenhart-Rothe R. The German Lower Extremity Functional Scale (LEFS) is reliable, valid and responsive in patients undergoing hip or knee replacement. *Qual Life Res* 2015;24:405-410.
14. Smeatham A, Powell R, Moore S, Chauhan R, Wilson M. Does treatment by a specialist physiotherapist change pain and function in young adults with symptoms from femoroacetabular impingement? A pilot project for a randomised controlled trial [published online February 27, 2016]. *Physiotherapy*. doi:10.1016/j.physio.2016.02.004.
15. Pavkovich R. Effectiveness of dry needling, stretching, and strengthening to reduce pain and improve function in subjects with chronic lateral hip and thigh pain: A retrospective case series. *Int J Sports Phys Ther* 2015;10:540-551.
16. Nepple JJ, Philippon MJ, Campbell KJ, et al. The hip fluid seal, part II: The effect of an acetabular labral tear, repair, resection, and reconstruction on hip stability to distraction. *Knee Surg Sports Traumatol Arthrosc* 2014;22:730-736.
17. Philippon MJ, Nepple JJ, Campbell KJ, et al. The hip fluid seal, part I: The effect of an acetabular labral tear, repair, resection, and reconstruction on hip fluid pressurization. *Knee Surg Sports Traumatol Arthrosc* 2014;22:722-729.
18. Domb BG, Stake CE, Lindner D, El-Bitar Y, Jackson TJ. Revision hip preservation surgery with hip arthroscopy: Clinical outcomes. *Arthroscopy* 2014;30:581-587.
19. Larson CM, Giveans MR, Samuelson KM, Stone RM, Bedi A. Arthroscopic hip revision surgery for residual femoroacetabular impingement (FAI): Surgical outcomes compared with a matched cohort after primary arthroscopic FAI correction. *Am J Sports Med* 2014;42:1785-1790.
20. Gupta A, Redmond JM, Stake CE, Dunne KF, Hammarstedt JE, Domb BG. Outcomes of revision hip arthroscopy: 2-year clinical follow-up. *Arthroscopy* 2016;32:788-797.