

Hip Pain After a Femoral Fracture: It Is Not Always Related to the Implant

BRIAN J. WHITE, MD; TARA K. HAWKES, BS; MACKENZIE M. HERZOG, MPH

abstract

The source of continued hip pain following fixation of traumatic femoral shaft fracture is not always clear. Intra-articular hip pathology is often overlooked when evaluating the etiology of residual pain. The purpose of this study was to describe cases of intra-articular hip pathology following traumatic femoral shaft fracture. This was a retrospective case series of patients presenting to a private practice orthopedic clinic from 2012 to 2015. Three patients presented with symptomatic intra-articular hip pathology following traumatic ipsilateral femoral shaft fracture. Patients who underwent hip arthroscopy with allograft labral reconstruction were identified retrospectively. Validated, subjective outcome scores administered included the Modified Harris Hip Score (MHHS), Lower Extremity Functional Scale (LEFS), visual analog scale (VAS) for pain, and VAS scale for patient satisfaction. Three patients were identified with residual, disabling groin pain after femoral shaft fracture fixation following a traumatic motor vehicle accident. All 3 patients were found to have a symptomatic ipsilateral labral tear. In 2 of the patients, an indentation on the lateral femoral head was appreciated, which was hypothesized to be caused by a subluxation event. All 3 patients were treated with arthroscopic hip surgery. At final follow-up, all 3 patients showed significant improvement in MHHS, VAS pain scores, level of satisfaction, and LEFS. Residual pain following ipsilateral femoral shaft fracture is not always related to implant. Intra-articular hip pathology should be considered in patients with lingering hip pain. [*Orthopedics*. 2016; 39(6):e1080-e1084.]

High-energy motor vehicle accidents often result in polytraumatic injuries.^{1,2} Injuries are prioritized based on threat to life, with the additional orthopedic goal of skeletal stabilization to

achieve early mobilization. Femoral shaft fractures are not uncommon in these types of traumatic mechanisms,^{1,2} and operative fixation is often necessary to stabilize the fracture.² Residual hip pain can be present

in some patients after appropriate healing of the femoral shaft fracture.³ The origin of the continued pain is not always clear. In some cases, implant removal may be recommended; however, this is not always successful.³ Although the source of residual symptoms can be multifactorial, the possibility of intra-articular hip pathology is often overlooked. Given the high energy associated with these injuries, it is possible that the patient can sustain both a femoral shaft fracture and a subluxation of the hip joint.^{4,5} Subluxation of the hip joint can cause intra-articular injuries, including injuries to the labrum and/or cartilage, and these pathologies can cause late, persistent hip pain and disability. The purpose of this study was to describe cases of intra-articular hip pathology following traumatic femoral shaft fracture.

The authors are from Western Orthopaedics (BJW, TKH), Denver, Colorado; and the Professional Research Institute for Sports Medicine, LLC (MMH), Chapel Hill, North Carolina.

Ms Hawkes and Ms Herzog have no relevant financial relationships to disclose. Dr White is a paid consultant for Smith & Nephew, Biomet, and ConMed Linvatec.

Correspondence should be addressed to: Brian J. White, MD, Western Orthopaedics, 1830 Franklin St, Ste 450, Denver, CO 80218-1217 (prismresearchconsulting@gmail.com).

Received: January 28, 2016; Accepted: June 13, 2016.

doi: 10.3928/01477447-20160714-03

MATERIALS AND METHODS

A retrospective chart review was performed to identify patients who underwent hip arthroscopy following ipsilateral femoral shaft fracture between 2012 and 2015. Three patients with persistent groin pain following fixation of an ipsilateral femoral shaft fracture were identified. Preoperative diagnosis was made based on clinical examination findings, radiographs and magnetic resonance imaging (MRI), and positive diagnostic injection.

All patients completed subjective, self-reported questionnaires to assess pain and function both pre- and postoperatively per standard of care at the authors' institution. Questionnaires included the Modified Harris Hip Score (MHHS),⁶ the Lower Extremity Functional Scale (LEFS),⁷ and visual analog scale (VAS) for average pain at rest, average pain with daily activities, and average pain with athletic activities. Overall subjective satisfaction with the procedure was also assessed using a VAS score for satisfaction from 1 to 10, where 1 was extremely dissatisfied and 10 was extremely satisfied.

Objective assessment was performed using a standardized data collection tool that is also used as standard of care at the authors' institution. Surgical data were collected, including assessment of the cartilage, labral tissue, femoroacetabular impingement (FAI), and capsule. Details regarding the surgical procedures performed, including graft length and number of anchors used for allograft labral reconstruction, were also systematically recorded.

RESULTS

Patient 1

A 42-year-old man presented for evaluation and treatment of continued left hip pain 4.5 years after a high-speed pedestrian vs motor vehicle accident. He sustained a Gustilo grade 3 open left femoral shaft fracture, bilateral tibial plateau fractures, right ankle fracture, and left proximal humeral fracture. All fractures were treated

with appropriate skeletal stabilization and healed by 11 months postoperatively. The patient had persistent left hip and groin pain. The intramedullary nail in the left femoral shaft fracture was removed, but pain persisted. At the time of consultation, the patient reported groin pain, significant pain following any activity, and painful locking and catching within the hip joint. Prior to this injury he was a police officer, and he was unable to return to work after the injury.

On physical examination, he had left hip full extension, flexion to 130°, internal rotation of 10°, and external rotation of 75° with pain at the end ranges of motion. Anterior impingement testing was positive with significant, reproducible pain. The patient scored 53 points on the preoperative MHHS and 47 points on the preoperative LEFS. The patient rated his hip a 6 at rest, 3 with daily activity, and 3 with athletic activity on the VAS pain scale. Anteroposterior (AP) pelvis and cross-table lateral radiographs demonstrated cam-type FAI and some calcification within the gluteus medius. A well-preserved lateral joint space was appreciated with no evidence of osteoarthritis. The femoral shaft fracture was healed and aligned. The alpha angle measured 69°, and the center-edge (CE) angle measured 31°. Review of MRI arthrogram suggested an acetabular labral tear. A diagnostic injection of 2 cc of 0.25% marcaine and 4 cc of 1% lidocaine was performed. This eliminated the patient's hip pain, leading to high suspicion of intra-articular hip pathology. The patient was offered hip arthroscopy to diagnose and treat intra-articular hip pathology.

During hip arthroscopy, the acetabular labrum was found to be extensively torn and significantly degenerative. There was an Outerbridge grade 4 cartilage lesion 5×15 mm in size on the edge of the acetabulum. In the peripheral compartment there was significant wear over the anterior aspect of the neck and cam morphology to the proximal femur. There was

also significant bruising and inflammation in the region of the iliopsoas tendon. Arthroscopically, the femoral neck was reshaped, removing excess bone to create a more normal concavity. The resulting alpha angle was to 43°. The labrum was not suitable for repair because it was chronically torn, hypertrophic, and degenerative. As such, after appropriate preparation of the acetabular rim, the labrum was reconstructed with a 7-cm frozen fascia lata allograft (AlloSource, Centennial, Colorado) and fixed with 5 anchors. A microfracture procedure was performed on the grade 4 lesion of the acetabulum. The iliopsoas tendon was also released arthroscopically at the myotendinous junction to create a functional lengthening. Dynamic testing once the hip was reduced showed the impingement was appropriately treated. The anterior portion of the capsulotomy was then closed. The patient underwent a supervised physical therapy program for approximately 6 months.

Seven months postoperatively, the patient rated his level of satisfaction with his hip at a 10. He reported a pain level of 1 at rest, 2 with daily activity, and 2 with athletic activity. The patient scored a 94 on the MHHS and 71 on the LEFS, resulting in a 30-point improvement in the MHHS and 24-point improvement in the LEFS. In addition, the patient rejoined the police force and is currently training cadets at the police academy.

Patient 2

A 34-year-old man presented with continued left hip pain 9 months after crashing his motorcycle. The crash resulted in a left grade 3 open distal femoral fracture, left closed clavicle fracture, and left open proximal tibial fracture. The fractures were treated with open reduction and internal fixation (ORIF). At 6 months following fixation, the femur showed incomplete union. The patient underwent plate and screw removal with revision to retrograde intramedullary nailing and bone grafting. The fracture ultimately

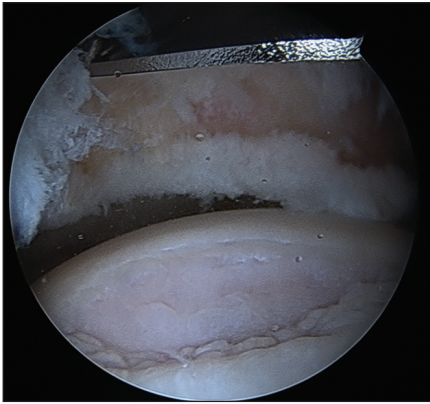


Figure 1: Intraoperative photograph of Patient 2 showing an indentation on the anterior portion of the lateral femoral head. This intraoperative finding supports the injury mechanism of a posterior subluxation that perched on the posterior wall of the acetabulum and created this indentation.

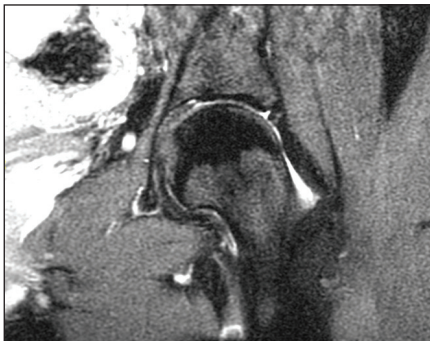


Figure 3: Preoperative magnetic resonance image of Patient 3 showing an acetabular labral tear.

healed, and the patient was able to return to work as a laboratory technologist; however, he continued to experience left hip and groin pain, which became especially painful while working. The patient used a prescription narcotic to treat hip pain and eventually developed a dependency on the drug. At the time of his visit, the patient reported groin pain while sitting, driving, walking, twisting, and squatting and also described moments of the hip joint feeling out of place.

On physical examination, the patient had normal left hip flexion and extension, 80° external rotation, and 5° internal rotation. Anterior impingement test was positive with significant pain. The patient scored 29 points on the MHHS and

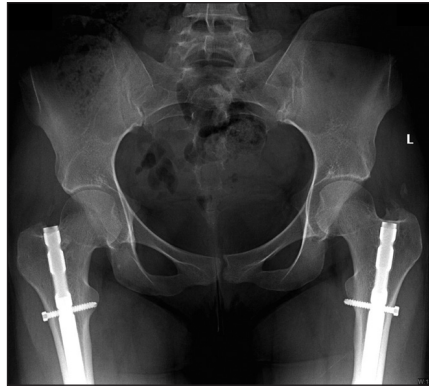

Figure 2: Preoperative anteroposterior radiograph of Patient 3 showing bilateral femoral nails, coxa profunda, pincer-type femoroacetabular impingement, and no evidence of arthritis or avascular necrosis.

14 points on the LEFS. On the VAS pain scale, pain level was 6 at rest, 8 with daily activity, and 10 with athletic activity. Anteroposterior and cross-table lateral radiographs revealed a healed and aligned femur with a retrograde nail in place. There was combination cam- and pincer-type FAI with a loose os acetabuli fragment. The lateral joint space was well preserved, and there was no evidence of osteoarthritis. The alpha angle measured 65°, and the CE angle measured 43°. Magnetic resonance imaging suggested a labral tear. A diagnostic injection took away the groin pain, suggesting intra-articular hip pathology as the source of continued pain. The patient was offered hip arthroscopy.

Arthroscopy showed normal cartilage on the femoral head. The labrum was extensively torn and degenerative. There was a large os acetabuli fragment measuring approximately 1 cm and a significant cam deformity on the proximal femoral neck. In addition, and consistent with his injury mechanism, there was an indentation on the anterior femoral head just medial to the head-neck junction (**Figure 1**). Arthroscopically, the femoral neck was reshaped, and the os fragment and the labrum were resected. The labrum was removed because it was too degenerative for repair. The labrum was then reconstructed with an 8.5-cm graft fixed with 6 anchors.

Two years postoperatively, the patient rated his level of satisfaction with his hip at a 10. The patient reported a pain level of 3 at rest, 4 with daily activity, and 4 with athletic activity. The patient scored 74 points on the MHHS and 68 points on the LEFS, for an overall improvement of 45 points in the MHHS and 54 points in the LEFS.

Patient 3

A 22-year-old woman presented with bilateral groin pain 2.5 years after a motor vehicle accident. She sustained bilateral femoral fractures, which were treated with antegrade intramedullary nails. The fractures were fixed, and the patient underwent physical therapy. The patient was able to return to activities of daily living; however, she continued to experience deep groin pain. At the time of consultation, the patient reported deep bilateral groin pain (left greater than right). Groin pain was experienced with long periods of sitting, twisting, and squatting and occasionally with sleep. The patient also reported painful anterior popping.

On physical examination, she had 125° forward flexion, 15° internal rotation, and 70° external rotation bilaterally. Anterior impingement maneuver was positive for both hips, with more significant pain replicated on the left side. The patient scored 54 points on the MHHS and 48 points on the LEFS. On the VAS pain scale, she scored a 2 at rest, 4 with daily activities, and 6 with athletic activities.

Anteroposterior and cross-table lateral radiographs showed combined cam- and pincer-type FAI (**Figure 2**). The lateral joint space measured 3.5 mm bilaterally. The alpha angle measured 65°, and the CE angle measured 36°. Magnetic resonance imaging showed bilateral labral tears (**Figure 3**). A diagnostic injection was performed on the left hip, which eliminated deep groin pain, suggesting intra-articular hip pathology as the source of persistent pain. Hip arthroscopy was offered.

Arthroscopy showed normal cartilage on the femoral head. The cartilage on the

acetabulum was compressed in the anterior superior quadrant and focally everted. There was an indentation on the lateral femoral head opposite of this. The labrum was significantly torn anteriorly, and, given its chronic eversion and poor quality, it was not felt to be repairable (**Figure 4**). The labrum was reconstructed with an 8.5-cm allograft fixed with 7 anchors (**Figure 5**).

At 8 months after her hip arthroscopy, the patient reported her level of satisfaction as a 10. Her VAS pain scores improved to 1 at rest, 2 with activity, and 4 with sport. She scored 96 points on the MHHS and 70 points on the LEFS, for an improvement of 42 points in the MHHS and 32 points in the LEFS. She was so pleased with her result that she had the other hip treated arthroscopically, with similar findings and treatment.

DISCUSSION

The cases presented support consideration of intra-articular hip pathology in patients with persistent hip and groin pain after high-energy femoral shaft fracture. High-energy trauma can subluxate or dislocate adjacent joints, creating significant intra-articular trauma. The indentation observed on the femoral head of 2 of the presented patients supports this phenomenon. It is hypothesized that the subluxation caused the intra-articular pathology in these cases. A similar occurrence has also been recognized in the knee, where several studies have documented ligamentous knee damage in conjunction with femoral fracture.^{8,9}

A consideration for intra-articular hip pathology was recommended several years ago by Watson et al¹⁰ in their report of a patient with residual pain following a fixated femoral shaft fracture. That patient was also found to have an acetabular labral tear. The addition of the 3 patients reported in the current study strengthens the conclusion that intra-articular hip pathology should be considered in cases of residual hip pain following femoral shaft fracture.

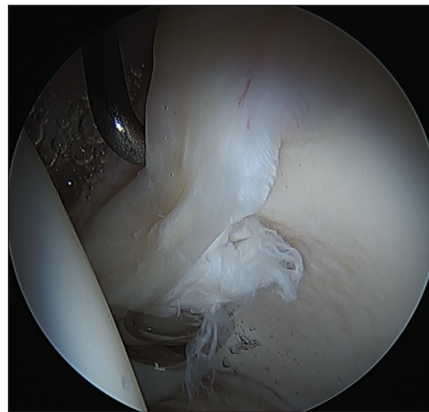


Figure 4: Arthroscopic view in traction from the anterolateral portal of Patient 3 showing a torn, shredded labrum in the center of the picture with the femoral head on the left and the cup on the right.

Continued hip pain following ORIF of a femoral shaft fracture is most commonly treated with removal of the implant.^{3,11} Implant removal successfully alleviates pain in many cases, but studies have also documented cases in which pain was not relieved. Dodenhoff et al³ reported the incidence of residual femoral pain in 80 patients who were treated for traumatic femoral fracture with a Grosse-Kempf nail. Seventeen patients had the nail removed due to pain, and of these, 6 (35%) patients continued to experience pain. Similarly, Brown et al¹² observed the incidence of late pain and implant removal after ORIF in 126 ankle fractures. Twenty-two patients underwent implant removal due to implant-related pain, but only 11 (50%) experienced a decrease in pain. These results suggest that consideration should be given to soft tissue and intra-articular pathology of the adjacent joints in situations where pain does not resolve following implant removal.

A comprehensive assessment provides crucial information for intra-articular hip pathology. Historically, sharp and dull groin pain, as well as hip pain experienced with extended standing, sitting, or walking, are commonly reported by patients with an acetabular labral tear.¹³ Provocative testing can further help with the diagnosis. A slight modification of the anterior

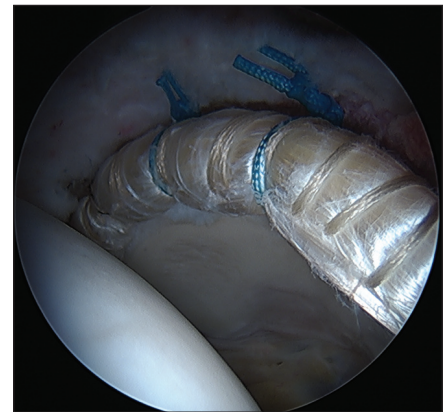


Figure 5: Arthroscopic view in traction of Patient 3 showing an 8.5-cm labral reconstruction with an IT Band (AlloSource, Centennial, Colorado) allograft.

impingement test where the patient is in a supine position with the affected hip flexed to 90° and the hip adducted across the midline is useful for assessment of labral tears.¹⁴ The hip is then internally rotated and moved from hip extension of 80° to hip flexion of 130° in an attempt to grind the anterior aspect of the femoral neck against the labral tear and the anterior cup. Decreased, guarded motion and anterior pain are indicative of labral pathology.

Radiographs of the hip, namely the AP pelvis and cross-table lateral views, are also useful to begin the evaluation of the joint.¹³ Assessment of the joint space is helpful for diagnosing the degree of cartilage wear. Radiographs also allow for critical evaluation of the shape of the acetabulum and the femoral head-neck junction. Femoroacetabular impingement is common, occurring in more than 90% of cases with labral pathology.¹⁵ Magnetic resonance imaging provides highly sensitive and accurate resolution of the labrum and associated tissue, making it an effective tool for identifying the location and magnitude of a labral tear.³ A final confirmation of the hip joint as the source of pain can be obtained with a diagnostic injection.¹⁶ Residual hip pain following femoral shaft fracture can be multifactorial. If the residual hip pain and disability are severe, an intra-articular injection of

lidocaine and marcaine can objectively quantify how much hip pain is truly originating from intra-articular hip pathology.

CONCLUSION

The intra-articular hip joint should be considered as a source of lingering hip pain in a patient with polytrauma after ipsilateral femoral shaft fracture. The possibility of an unrecognized hip subluxation at the time of injury could create a tear of the acetabular labrum and other intra-articular pathology. The presented cases demonstrate patients with residual, severe, disabling groin pain following fracture fixation. Increased awareness of this diagnosis can lead to a faster recovery process and help patients attain a full recovery from a devastating injury.

REFERENCES

1. Kwong Y, Chong M, Hassan A, Kelly R. Severity of injuries associated with femoral fractures as a result of motor vehicle collisions. *Arch Orthop Trauma Surg.* 2006; 126(7):454-457.
2. Bucholz RW, Jones A. Fractures of the shaft of the femur. *J Bone Joint Surg Am.* 1991; 73(10):1561-1566.
3. Dodenhoff RM, Dainton JN, Hutchins PM. Proximal thigh pain after femoral nailing: causes and treatment. *J Bone Joint Surg Br.* 1997; 79(5):738-741.
4. Milenkovic S, Mitkovic M, Saveski J, et al. Avascular necrosis of the femoral head in the patients with posterior wall acetabular fractures associated with dislocations of the hip [in Serbian]. *Acta Chir Jugosl.* 2013; 60(2):65-69.
5. Giannoudis PV, Kontakis G, Christoforakis Z, Akula M, Tosounidis T, Koutras C. Management, complications and clinical results of femoral head fractures. *Injury.* 2009; 40(12):1245-1251.
6. Byrd JW, Jones KS. Prospective analysis of hip arthroscopy with 2-year follow-up. *Arthroscopy.* 2000; 16(6):578-587.
7. Binkley JM, Stratford PW, Lott SA, Riddle DL. The Lower Extremity Functional Scale (LEFS): scale development, measurement properties, and clinical application. North American Orthopaedic Rehabilitation Research Network. *Phys Ther.* 1999; 79(4):371-383.
8. Emami Meybodi MK, Ladani MJ, Emami Meybodi T, et al. Concomitant ligamentous and meniscal knee injuries in femoral shaft fracture. *J Orthop Traumatol.* 2014; 15(1):35-39.
9. Moore TM, Patzakis MJ, Harvey JP Jr. Ipsilateral diaphyseal femur fractures and knee ligament injuries. *Clin Orthop Relat Res.* 1988; 232:182-189.
10. Watson D, Walcott-Sapp S, Westrich G. Symptomatic labral tear post femoral shaft fracture: case report. *J Orthop Trauma.* 2007; 21(10):731-733.
11. Toms AD, Morgan-Jones RL, Spencer-Jones R. Intramedullary femoral nailing: removing the nail improves subjective outcome. *Injury.* 2002; 33(3):247-249.
12. Brown OL, Dirschl DR, Obrebsky WT. Incidence of hardware-related pain and its effect on functional outcomes after open reduction and internal fixation of ankle fractures. *J Orthop Trauma.* 2001; 15(4):271-274.
13. Beaulé PE, O'Neill M, Rakhra K. Acetabular labral tears. *J Bone Joint Surg Am.* 2009; 91(3):701-710.
14. Lewis CL, Sahrman SA. Acetabular labral tears. *Phys Ther.* 2006; 86(1):110-121.
15. Tanzer M, Noiseux N. Osseous abnormalities and early osteoarthritis: the role of hip impingement. *Clin Orthop Relat Res.* 2004; 429:170-177.
16. Pateder DB, Hungerford MW. Use of fluoroscopically guided intra-articular hip injection in differentiating the pain source in concomitant hip and lumbar spine arthritis. *Am J Orthop (Belle Mead NJ).* 2007; 36(11):591-593.